

VOLUME 12, NO. 2

# ISAPS NEWS

OFFICIAL NEWSLETTER OF THE INTERNATIONAL  
SOCIETY OF AESTHETIC PLASTIC SURGERY



## GLOBAL PERSPECTIVES: OTOPLASTY

*In Nature, the Spiral Curve Creates Beautiful Architecture  
Such as the Shell of the Nautilus*

- Akira Yamada, MD, PhD



# MESSAGE FROM THE EDITOR

## BOARD OF DIRECTORS

**PRESIDENT**  
Renato Saltz, MD, FACS  
Salt Lake City, Utah, US  
[rsaltz@saltzplasticsurgery.com](mailto:rsaltz@saltzplasticsurgery.com)

**PRESIDENT-ELECT**  
Dirk Richter, MD, PhD  
Köln, GERMANY  
[d.richter@krankenhaus-wesseling.de](mailto:d.richter@krankenhaus-wesseling.de)

**FIRST VICE PRESIDENT**  
Nazim Cerkes, MD, PhD  
Istanbul, TURKEY  
[ncerkes@hotmail.com](mailto:ncerkes@hotmail.com)

**SECOND VICE PRESIDENT**  
Lina Triana, MD  
Cali, COLOMBIA  
[linatriana@drlinatriana.com](mailto:linatriana@drlinatriana.com)

**THIRD VICE PRESIDENT**  
W. Grant Stevens, MD, FACS  
Marina del Rey, California, US  
[drstevens@hotmail.com](mailto:drstevens@hotmail.com)

**SECRETARY**  
Gianluca Campiglio, MD, PhD  
Milan, ITALY  
[info@gianlucacampiglio.it](mailto:info@gianlucacampiglio.it)

**TREASURER**  
Kai-Uwe Schlaudraff, MD, FEBOPRAS  
Geneva, SWITZERLAND  
[schlaudraff@concept-clinic.ch](mailto:schlaudraff@concept-clinic.ch)

**HISTORIAN**  
Thomas S. Davis, MD  
Hershey, Pennsylvania, US  
[drtomdavis@aol.com](mailto:drtomdavis@aol.com)

**PARLIAMENTARIAN**  
Arturo Ramirez-Montana, MD  
Monterrey, MEXICO  
[docarturo@gmail.com](mailto:docarturo@gmail.com)

**EDUCATION COUNCIL CHAIR**  
Vakis Kontoes, MD, PhD  
Athens, GREECE  
[vakiskont@gmail.com](mailto:vakiskont@gmail.com)

**EDUCATION COUNCIL VICE CHAIR**  
Ozan Sozer, MD  
El Paso, Texas, US  
[doctor@elpasoplasticsurgery.com](mailto:doctor@elpasoplasticsurgery.com)

**NATIONAL SECRETARIES CHAIR**  
Peter Desmond Scott, MD  
Benmore, SOUTH AFRICA  
[peters@cinet.co.za](mailto:peters@cinet.co.za)

**PAST PRESIDENT**  
Susumu Takayanagi, MD, PhD  
Osaka, JAPAN  
[info@mega-clinic.com](mailto:info@mega-clinic.com)

**TRUSTEES**  
Lokesh Kumar, MD  
New Delhi, INDIA  
[drlokesh2903@gmail.com](mailto:drlokesh2903@gmail.com)

Carlos Oscar Uebel, MD, PhD  
Porto Alegre, BRAZIL  
[carlos@uebel.com.br](mailto:carlos@uebel.com.br)

**EXECUTIVE DIRECTOR**  
Catherine Foss  
Hanover, New Hampshire, US  
[isaps@isaps.org](mailto:isaps@isaps.org)

Welcome to this issue of *ISAPS News*!

Plans are well underway for the 24th Congress of ISAPS. Including surgeons and their office staff, exhibitors and families, we already have well over 1800 people from 87 countries coming to Miami Beach. If you have not registered yet, please do it now to be part of this amazing global aesthetic education event. Master Classes and Cadaver Labs are registering well and our social events will be outstanding. Be sure to buy tickets to the final event at Nikki Beach.

Abstracts submitted for presentation at this Congress exceed expectations at 555. Those that the reviewers accepted are listed in this issue and number close to 400. Congratulations to the presenters and their co-authors.

The Global Perspectives Series in this issue highlights Otoplasty with a fascinating article about its history by Dr. Riccardo Mazzola and eleven superb articles from authors in Belgium, Brazil, China, Germany, Italy, South Africa, Spain and the US. I was surprised to learn about the connection with a pioneer in this field, Dr. Radford C. Tanzer, and our Executive Director, Catherine Foss. We dedicate this series of articles to his memory.

As in every issue, you will read about our extensive education program as highlighted by the Chair of the Education Council, Dr. Vakis Kontoes, and described in detail not only by our President, Dr. Renato Saltz, but by the organizers of events in Ukraine, South Africa, Spain, and Panama as well as Dr. Nazim Cerkes who participated in our ongoing Visiting Professor Program. Our mission of *Aesthetic Education Worldwide*® continues to grow by educating surgeons globally – with the end result always being the safety of our patients. Dr. Ozan Sozer updates us on the activities of the Global Accreditation Committee with the eventual goal of appropriately credentialing surgical facilities that comply with stratified regulations.

Another excellent article by Dr. James Fernau representing our Patient Safety Committee offers practical information about BIA-ALCL, and Dr. Ivar van Heijningen, ISAPS Membership Committee Chair and current President of EASPS, provides an excellent guide for surgeons related to the new GDPR regulations now in effect in the EU.

Twenty-nine elections of National Secretaries have been carried out by the Executive Director since the beginning of the year adding many new members to the National Secretary group. Another two elections are in process as of the publication of this issue.

We have lost three members in this period: Dr. Ricardo Baroudi (Brazil), Dr. Ghaith Shubailat (Jordan) and Dr. Marianne Medot (Belgium). We thank the authors of their obituaries for providing us with a glimpse into the lives of these extraordinary individuals.

While not unusual in a Congress year, new membership applications have been extraordinary highlighting not only interest in attending this global event, but in joining our ISAPS family. From March through May, 308 applications were processed and approved – and the new members are listed at the back of this issue. We heartily welcome them all.

I hope you enjoy reading this issue of *ISAPS News*.

Warm Regards,

J. Peter Rubin, MD  
Editor-in-Chief

## CONTENTS

Message from the Editor	2
Message from the President	3
Global Alliance	6
Patient Safety	8
Feature	10
GDPR Surgeon Guide	11
ISAPS Privacy Policy	13
Education Council Report	15
ISAPS Course Reports	16
Guess Who	19
Where in the World?	19
Global Accreditation	20
Humanitarian Activities	23
Visiting Professor Program	24
National Secretaries Report	25
Journal Update	26
Marketing	27
Global Perspectives	29
CONGRESS	43
Short Case Study	55
History	56
In Memoriam	58
New Members	62
Meetings Calendar	64



# MESSAGE FROM THE PRESIDENT

## AESTHETIC EDUCATION

Our primary mission of *Aesthetic Education Worldwide®* remains the main focus of your Board of Directors and the Education Council.

Since the beginning of 2018, we have offered three ISAPS Courses and four Symposia and endorsed 25 programs. The amazing work of Vakis Kontoes and Ozan Sozer, Chairs of the Education Council, promises another fantastic educational year like we had in 2017. I have personally attended many meetings in the first six months of this year and in every single one I proudly represented all our members and the Board of Directors. I shared with every audience the ISAPS presentation updating members and non-members alike about what we are doing and the many benefits of being a member of ISAPS.

In the last few months, I attended back-to-back meetings in Central and South America: the *American Brazilian Aesthetic Meeting (ABAM)* in Florianopolis, Brazil, the *Highlights of Plastic Surgery* meeting in Panama, and then back to Brazil for the 19th edition of Carlos Uebel's *International Symposium* in São Paulo. I am happy to share with you the enormous enthusiasm and support I have experienced among these audiences regarding ISAPS. In São Paulo, I was honored to present the Ivo Pitangy Lecture. He was a great friend of mine who opened the doors of his clinic in Rio to me when I visited him in the early 90s immediately after my plastic surgery residency.



Figure 1 - With Dr. Niveo Steffen and Dr. Carlos Uebel in Sao Paulo.

I was also very happy to meet with my dear friend, and the new President of the Brazilian Society, Dr. Niveo Steffen, who is opening Brazil to ISAPS again.

Then I flew to Korea to attend the very first joint meeting of the *Korean Association of Plastic Surgeons (KAPS)*, the *Korean Society for Aesthetic Plastic Surgery (KSAPS)* and *ISAPS*. I thank Dr. Eun-Sang Dhong and Dr. Man-Koon Suh for their hard work in putting this together and opening the doors of Korean plastic surgery to ISAPS



Figure 2 - The four societies' presidents.

Earlier this month, I was in Lyon, France attending the *French Aesthetic Society Meeting, SOFCEP*. ISAPS had a very large presence there with a full day dedicated to an ISAPS-SOFCEP joint educational activity with the enthusiastic support of Gilbert Vitale (President), Michel Rouif (Past-President) and Sebastian Garson (President-Elect) and attendance of nearly 500 French colleagues. The ISAPS booth was very busy with new members signing up and intense registrations of plastic surgeons and exhibitors for the Biennial Congress in Miami Beach this fall.



Figure 3 - Leaders of KAPS, KSAPS and ISAPS celebrate together in Seoul during the first meeting of the three societies in Seoul in April.



Figure 4 - Drs. Catherine Bergeret-Galley, Sebastien Garson, Renato Saltz, Michel Rouif and Gilbert Vitale.



Figure 5 - From the right, Renato Saltz, Fabian Cortinas, Bianca Knoll, Alison Thornberry, Catherine Foss, Michel Rouif and two new members of ISAPS - at the booth in Lyon.

## BOARD OF DIRECTORS MEETING IN NEW YORK CITY

Your Board of Directors and staff were very busy during the American Society for Aesthetic Plastic Surgery (ASAPS) Annual Meeting in New York in April. Several activities related to ISAPS took place including a Journal Retreat, a Strategic Planning Meeting, a Board of Directors Meeting, an informal National Secretaries Meeting, a Humanitarian Committee Meeting, an ISAPS update presentation given to the ASAPS Board of Directors not to mention a very busy, larger than usual, ISAPS exhibit booth. We congratulate Grant Stevens, ISAPS 3rd Vice President, for becoming the President of ASAPS during the New York meeting.



Figure 6 - The Team at the ISAPS Booth in New York - enjoying their mojitos!

## GLOBAL ACCREDITATION PROGRAM

The Global Accreditation Committee has completed a set of rules and regulations that can be applicable throughout the world. The committee, under the leadership of Ozan Sozer and Ivar van Heijningen, are now in the process of dividing these into three classifications: Basic (absolutely necessary), Intermediate and Advanced. Once this process is completed, they will develop procedures for inspecting and accrediting facilities worldwide.

Continued on Page 4



## PRESIDENT'S MESSAGE CONTINUED

### AESTHETIC PLASTIC SURGERY JOURNAL

It gives me great satisfaction to welcome Dr. Lee Pu as the new Associate Editor of our Journal. Dr. Pu has an outstanding resume and career and will provide Dr. Guyuron with the necessary help and support much needed to continue to grow our journal. Welcome Aboard, Lee!

### GLOBAL SURVEY

Thank you to all who completed the 2018 survey. It is our best tool to watch what is happening in the aesthetic world, to learn about trends, to share our numbers with our colleagues and the public and to provide to world media with reliable information on aesthetic surgery worldwide. The ISAPS Global Survey is the single largest survey conducted on cosmetic procedures in the world. Last year alone, the results generated over 6200 editorial articles in key media in 96 countries and generated an estimated **US\$300 million in global publicity for the specialty of Aesthetic Plastic Surgery**. This survey is the most important public relations initiative for our specialty – regardless of whether you are a member of ISAPS or not. Our data is collected and analyzed by an independent research company, Industry Insights, before being sent back to ISAPS for global distribution. At this time, we have a waiting list of more than 3,000 media contacts in 46 countries anticipating the release of this year's statistics.

***THE GREATEST AESTHETIC EDUCATION ON EARTH is still 5 months away and we just passed 1300 registrations!***

We have 388 confirmed faculty with a spectacular scientific program distributed among four ballrooms for Face, Breast & Body and ISAPS Business School, in addition to 64 Master Classes, three Cadaver Labs, our first Women Plastic Surgeons' Symposium, a Residents and Fellows Forum and rooms dedicated to free paper presentations. We received 555 abstracts from around the world and 386 were selected for presentations by the reviewers. Industry support has been outstanding with 115 exhibitors confirmed and more coming. We thank them for their continued support of ISAPS.

Plan to stay until Sunday to attend the most spectacular panels. ASAPS, EASAPS and OSAPS are bringing their top speakers to present during their panels at the opening of the Sunday Scientific Sessions. After that, we will have a Vaginal Rejuvenation Panel, a Gluteal Augmentation Panel and the most anticipated Cybersecurity Panel with experts including an FBI agent specialized in this complex and scary field.

### SOCIAL EVENTS

On Wednesday, October 31st, we kept the evening open after a long day of Cadaver Labs, the Residents and Fellows Forum and the Women Plastic Surgeons' Symposium for you to go out to explore the area. Bring your costume and enjoy

the friendly, fun and unpredictable experience of Halloween in South Florida – like nothing you have never seen before!

On Thursday, we will have the traditional Opening Ceremonies and Welcome Reception at the Miami Beach Convention Center. It will be unique and a great way to welcome our friends and colleagues from all over the world to South Florida.

Friday evening is reserved for the Faculty Dinner (by invitation) where we will recognize all the contributors who will have so generously made this event The Greatest Aesthetic Education on Earth.

Finally, on Saturday night you will not want to miss our great farewell party at Nikki Beach, one of the most exquisite and fun places in South Florida. Great food, great drink, great music, and a last chance to visit with new and old friends you will meet at this Congress in a unique and totally casual atmosphere.

Plan to come early in the week and leave home only on Sunday afternoon. You do not want to miss any of the 36 Scientific Sessions, 64 Master Classes, the fantastic Panels, Fresh Cadaver Dissections and fun social events of the 24th ISAPS Biennial Congress in South Beach.

### MEMBERSHIP

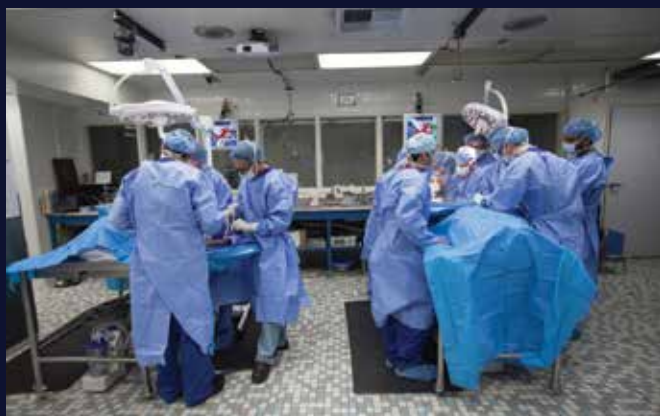The increase in membership and our great geographic distribution has been one of the top priorities during my tenure. I am happy to report that we have a new record number of 3,664 members in 103 countries. Already this year, we have added more members, in five months, than in all of 2017 and 102 more are in the process of providing the required documents to become members. Fast track admissions have arrived from eight countries and a few more are expected soon.

### OBITUARIES

It is with great sadness that I report the passing of Dr. Ricardo Baroudi on April 30 in Campinas, Brazil. He was one of the most prominent Brazilian plastic surgeons and a personal friend of mine. Among his many achievements was his ISAPS Presidency from 1995 to 1997. Two other ISAPS Members also passed away recently: Dr. Ghaith Shubailat of Jordan and Dr. Marianne Medot of Belgium. Please take a moment to read the fine articles about each of them in this issue of ISAPS News. We will miss them.



Renato Saltz, MD, FACS  
ISAPS President



**SIGN UP FOR A THREE HOUR  
CADAVER LAB ON WEDNESDAY**  
[www.ISAPSMiami2018.com](http://www.ISAPSMiami2018.com)

Cadaver Lab I - Face & Browlift  
Cadaver Lab II - Rhinoplasty  
Cadaver Lab III - Mastopexy & Labiaplasty

**SPACE IS LIMITED**

Refer to page 54 for more information

# EPSTEIN ABDOMINOPLASTY RETRACTOR

As the trend in today's abdominoplasties is towards less upper lateral undermining, the upper tunnel has become narrower. During the dissection of this tunnel, it is difficult to maintain countertraction with available instrumentation. The Epstein Abdominoplasty Retractor was designed to assist in the performance of the dissection of the upper abdominal tunnel. The ergonomic handle is easily held by the surgical assistant. It is available in several blade lengths so as to best fit the anatomy of the patient: whether the tunnel is long or short, there is a retractor to provide the best mechanical advantage in yielding exposure and reducing fatigue. The widened, curved working end spreads the tissues of the upper skin flap apart as the teeth gently hold them in place without slippage. The leading edge of the dissection is easily seen and maintained, facilitating effortless cautery elevation of the skin flap from the muscle fascia. The retractor is also extremely helpful in elevating the abdominal skin flap over the narrow tunnel so that the underlying muscle fascia can be plicated.

- Designed to assist in the performance of the dissection of the upper abdominal tunnel
- The wide curved working end spreads and holds the tissue of the upper skin flap apart
- Facilitates cautery elevation of the skin flap from the muscle fascia
- Extremely helpful in elevating the skin flap over the narrow tunnel for muscle fascia plication

**ASSI.ABR31726**

**Epstein Abdominoplasty Retractor**  
80x27mm blade with 60mm wide working end with teeth and ergonomic handle

**ASSI.ABR31826**

**Epstein Abdominoplasty Retractor**  
110x27mm blade with 60mm wide working end with teeth and ergonomic handle

**ASSI.ABR32026**

**Epstein Abdominoplasty Retractor**  
140x27mm blade with 60mm wide working end with teeth and ergonomic handle

**ASSI.ABR31926**

**Epstein Abdominoplasty Retractor**  
160x27mm blade with 60mm wide working end with teeth and ergonomic handle

**assi**®   
ACCURATE SURGICAL & SCIENTIFIC INSTRUMENTS®  
For diamond perfect performance®

accurate surgical & scientific instruments corporation

300 Shames Drive, Westbury, NY 11590

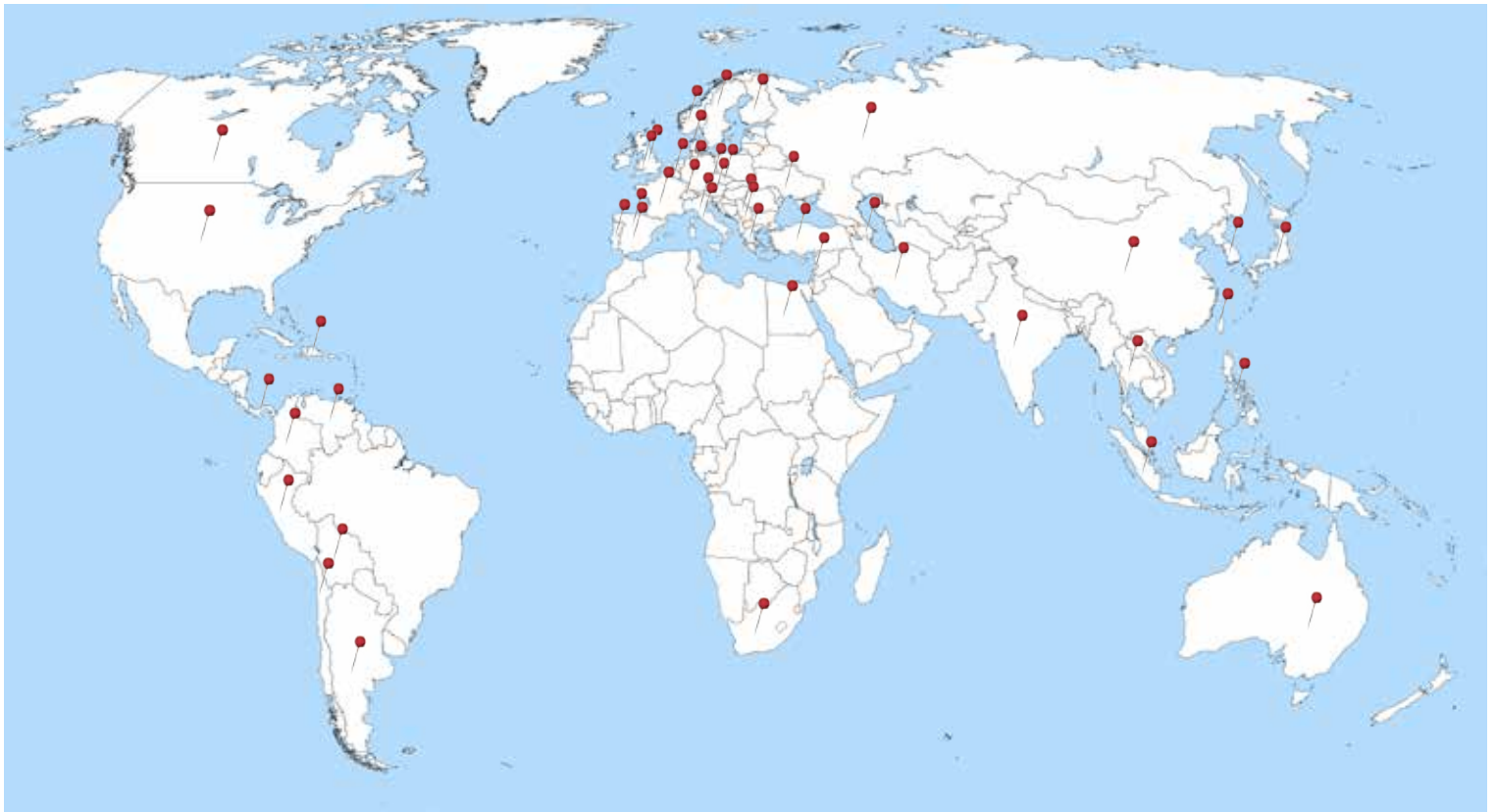800.645.3569 516.333.2570 fax: 516.997.4948 west coast: 800.255.9378

E-Mail: [orders@accuratesurgical.com](mailto:orders@accuratesurgical.com) Internet: [www.accuratesurgical.com](http://www.accuratesurgical.com)

Designed By:  
Mark D. Epstein,  
M.D., F.A.C.S.,  
Stony Brook, NY

# ISAPS GLOBAL ALLIANCE PARTICIPATING SOCIETIES SPAN THE GLOBE

---



ISAPS is very proud to have welcomed 54 national societies into the Global Alliance. This opens a line of communication at the Presidential level to create a strong, international presence for plastic surgery that benefits all members of the group. Several quiet initiatives developed by the Alliance have already influenced needed legislative changes in several countries.



# ALLIANCE MEMBER FOCUS: ITALIAN SOCIETY OF PLASTIC, RECONSTRUCTIVE, AND AESTHETIC SURGERY (SICPRE)



**ADRIANA CORDOVA, MD**

Italy

President, SICPRE

Plastic surgery in Italy has ancient origins. Between 1400 and 1600, surgery was mainly performed by barbers and traders who practiced in hiding between experience and witchcraft. In this scenario, two families of surgeons, the Branca in Sicily, and the Viano in Calabria, are acknowledged for early surgical techniques regarding nose reconstruction with local flaps and with a flap harvested from the arm (1).

The importance of the Branca family in the fifteenth-century was so crucial that they were counted among the marvels of that time in the work "Annales omnium temporum" by the historian and humanist Pietro Ranzano (1426 -14939) (2).

The technique of the surgeon/barbers Branca and Viano was described by Leonardo Fioravanti (3), medical doctor graduated in Bologna, whose work probably inspired the contemporary Gaspare Tagliacozzi.

The scientific breakthrough in plastic surgery happened with the publication of the first plastic surgery book "De Curtorum Chirurgiae per Insitionem" by Gaspare Tagliacozzi from Bologna (4).

Doctor Tagliacozzi, who is considered the first "true" plastic surgeon in history, described in detail a nasal reconstruction technique, using a skin flap raised from the arm and transferred to the facial defect using a complex mechanism of strings, supports and synthesis, that has been referred to as the "Italian method."

From the work of Tagliacozzi, early questions were raised regarding ethics in cosmetic surgery. He was the first to mention the rightness of surgery not only for healing, but also for "restoring dignity" to people.

The Italian Society of Plastic, Reconstructive, and Aesthetic Surgery (SICPRE) is the eldest, most prestigious and representative association of Italian plastic surgeons. Founded in Rome in 1934, SICPRE includes the majority of Italian plastic surgery specialists among all the Italian regions and accounts more than 1,000 associates.

SICPRE is a scientific association open only to those who have obtained the academic qualification of Specialist in Plastic Reconstructive and Aesthetic Surgery. SICPRE emphasizes the similarities in the techniques and purpose of plastic, reconstructive and aesthetic surgery, which share the same identity.

In recent years, SICPRE has worked in close contact with the Italian Ministry of Health, being a reference point for several scientific and social issues such as information on breast implants and the creation of an implant national registry.

SICPRE has also played an important international role, due to official affiliations with prestigious scientific associations worldwide, including:

- UEMS, European Union of Medical Specialists, headed by the European Board of Plastic, Reconstructive and Aesthetic Surgery
- ICOBRA, Project that aims to coordinate the breast implant registries around the world
- ICOPLAST, International confederation of plastic surgery societies officially recognized
- ASPS, American Society of Plastic Surgeons
- SBPCP, Brazilian Society of Plastic Surgery

In 2013, SICPRE has established an official affiliation with the International Society of Aesthetic Plastic Surgery (ISAPS). This collaboration, along with active participation in ISAPS training initiatives, has enhanced SICPRE's commitment to training and updating professionals in the field of aesthetic surgery with the aim of finalising a code of ethics for its members and containing the extravagant show and commodification of aesthetic surgery.

The most recent actions adopted by SICPRE in the field of aesthetic surgery have been:

- A better appreciation of the network of private surgeons in the society with a greater involvement in its activities and appointments
- Affiliation with *Aesthetic Plastic Surgery*, the official ISAPS journal
- The promotion of surveys and multicentric clinical studies in the field of aesthetic surgery
- Support for young residents or specialists in plastic surgery through easier access to training activities and publishing of scientific work.

From a long past, rich in history, through collaborations and synergistic work with ISAPS, SICPRE aims to be a vector for the scientific and ethical progress of aesthetic surgery today and in the future.

## References

- 1) Micali G. The Italian contribution to plastic surgery. *Ann Plast Surg.* 1993 Dec;31(6):566-71.
- 2) *Annale omnium temporum* - manoscritto originale in otto conservato presso la Biblioteca Comunale di Palermo
- 3) Fioravanti L: *I Tesori della Vita Humana*. Venezia: Sessa, 1570.
- 4) Tagliacozzi G: *De Curtorum Chirurgia per Insitionem*. Venezia, Meiello 1597.
- 5) Santoni-Rugiu P, Mazzola R. Leonardo Fioravanti (1517-1588): a barber-surgeon who influenced the development of reconstructive surgery. *Plast Reconstr Surg.* 1997 Feb;99(2):570-5.



**SICPRE**  
Società Italiana di Chirurgia Plastica Ricostruttiva ed estetica

# BIA-ALCL UPDATE: A PRACTICAL GUIDE FOR PLASTIC SURGEONS



**JAMES FERNAU, MD**  
United States  
Member, ISAPS Patient Safety Committee

In 2016, the world health organization designated breast implant associated anaplastic large cell lymphoma BIA-ALCL as a T cell lymphoma that can develop following breast implants. It often presents as a delayed fluid collection around textured implants or surrounding scar capsule. It is not a breast cancer; it is a lymphoma. The exact number of cases remains difficult to determine due to significant limitations in worldwide reporting and lack of global breast implant sales data. At this time, most data suggest that BIA-ALCL occurs more frequently following implantation of breast implants with textured surfaces rather than those with smooth surfaces. Current data report 529 cases of BIA-ALCL with 16 deaths worldwide. Five of the deaths reported where from the United States. The FDA in the United States has reported 414 cases of BIA-ALCL with 9 deaths. Some of these reported cases and deaths were international cases. The Plastic Surgery Foundation's PROFILE breast implant registry has reported 201 cases of BIA-ALCL with 5 deaths. PROFILE stands for Patient Registry and Outcomes For breast Implants and anaplastic large cell Lymphoma (ALCL) etiology and Epidemiology. <https://www.thepps.org/research/registries/profile> This is the preferred registry which is supported by ASPS and the FDA. Reporting from the FDA is somewhat confusing due to unconfirmed cases and duplicated cases. The PROFILE registry is more accurate with unique and confirmed cases. Currently, M.D. Anderson Hospital in Houston, Texas is recognized by the FDA as a centralized tissue repository.

Finally, prevention is a necessary step to avoid bacterial contamination of implants and subsequent ALCL. Scientific papers have revealed the efficacy of Betadine to reduce bacterial contamination. 10% Povidone iodine is the full strength of Betadine. This solution is more effective when mixed 50-50 with sterile injectable saline because the latter releases the iodine allowing it to kill bacteria. Another scientific study has shown the efficacy of 0.025% hypochlorous acid eliminating planktonic bacteria from the biofilm including *Ralstonia* spp which has been implicated in ALCL. Other studies have shown triple antibiotics to be of value in treating bacterial biofilms. As surgeons, it behooves us to take every possible precaution to prevent complications in our patients. Considering the use of half strength Betadine and 0.025% hypochlorous acid is prudent. These solutions can be injected directly into the thermoform packaging on the operating room back table and/or used for pocket irrigation. Furthermore, applying the concept of the no touch technique, glove change and using insertion funnels are beneficial in eliminating capsule contracture. Other recommendations include the use of inframammary incisions, atraumatic dissection with careful hemostasis, use of a dual plane pocket, avoiding dissections in the breast parenchyma, avoiding drains and closing the wound in layers. It is clear more studies need to be done and we need to start thinking proactively with our smooth implantation devices.

I have included a discussion by Dr. Ali A. Qureshi and Dr. Mark Clemens which examines a clinical case of BIA-ALCL and concludes with a protocol for managing possible cases of BIA-ALCL which present as delayed (> 1 year) seromas.

## **Delayed Breast Seromas after Breast Augmentation and Reconstruction: Could it be BIA-ALCL?**

Ali A. Qureshi, MD and Mark W. Clemens, MD

### **Introduction**

Earlier this spring, the FDA released patient safety communications agreeing with the World Health Organization's provisional classification of Breast Implant Associated - Anaplastic Large Cell Lymphoma (BIA-ALCL) as a newly recognized malignancy. Currently, the FDA in the United States has reported 414 cases of DTA-ALC adverse events and 9 deaths which has heightened awareness of plastic surgeons and anxiety among patients. But as plastic surgeons, who should we be working up for BIA-ALCL and how?

### **Case Example**

Take the example of Monica, a 40-year old woman who had a primary breast augmentation eight years ago with a textured device in a sub-glandular plane. She presents to your office after recently moving from another state with asymmetric swelling of her left breast. She denies any trauma, fevers or open wounds or palpable masses. She also had a mammogram earlier this year before any swelling that was BIRADS-1 with no concern for malignancy.

### **Guidelines**

The National Comprehensive Cancer Network released guidelines in 2016 to specifically help oncologists and surgeons with the diagnosis and treatment of BIA-ALCL using best available evidence-based medicine. These recommendations have been adopted by ASAPS as well as our sister organizations, ISAPS and ASPS.

Here's what we know about BIA-ALCL presentations:

- 80% present as a fluid collection but 40% also present as a mass with some presenting with both
- 8% present with description of capsular contracture symptoms but many times this is a rapid hardening of the breast from the accumulation of a large volume seroma within 24-48 hours
- 8% describe lymphadenopathy and 2% an overlying rash
- Median onset is 8 years with a range of 2 - 28 years

### **Evaluation and Diagnosis**

Now back to Monica. A thorough physical examination should be performed to assess for any masses or lymphadenopathy and an exam of the contralateral breast should be done. A high index of suspicion on the part of the clinician is critical for appropriate management of these patients. The next step should be diagnostic evaluation of the fluid collection and fine needle aspiration. Ultrasound has been found to have the best sensitivity and specificity for seromas/effusions suspected of being BIA-ALCL. If inconclusive, an MRI can be considered. If the patient presents with a mass, this could represent a different breast cancer and should be worked up by a breast oncologist. Because BIA-ALCL does not present with calcifications, mammography is not a recommending screening or diagnostic tool. The aspiration can be performed by the plastic surgeon in the clinic setting if equipped with the appropriate tools such as ultrasound to displace and protect the implant. However, effusion aspiration can also be performed by interventional radiology.



Once the fluid is obtained, don't throw the fluid away! BIA-ALCL cannot be diagnosed without sending the aspirated fluid for cytology. The pathologists should be asked to assess for BIA-ALCL and the pathologists will look for large anaplastic cells cell block cytology as well as CD30 expression on immunohistochemistry. The fluid needs to be screened for CD30 immunohistochemistry as routine pathology will miss the diagnosis. A pathologist will then perform flow cytometry to assess for clonal expansion of a single T-cell. The fluid should be sent for aerobic and anaerobic cultures as well.

What about ALK protein or translocations? BIA-ALCL is always ALK-translocation negative. ALK testing is not a screening test but is used to differentiate BIA-ALCL from other aggressive diseases such as systemic ALCL, which has a higher mortality (up to 80% at three years).

BIA-ALCL is the diagnosis of an effusion or seroma around a breast implant or associated with the capsule if these criteria are met:

- Cells are CD30 positive on immunohistochemistry
- Cell block cytology shows large anaplastic cells occurring in an effusion or on the luminal surface of a breast capsule
- Flow cytometry shows a single T-cell clonal expansion
- ALK protein or translocation negative on gene testing

The results of the testing will guide the next steps in management and have been published in the *Aesthetic Surgery Journal*, including staging and treatment algorithms for BIA-ALCL.

### Back to the Case

In Monica's case, her testing returns CD30 negative and no further testing is warranted. She can be treated for a benign delayed seroma. Rarely, there can be cases like Monica's where CD30 testing is positive and the remainder of testing is negative as CD30 is a nonspecific marker for an activated T-cell. Normally, about 1-5% of normal, circulating lymphocytes are CD30 positive. Some patients will have rare, scant CD30 positive cells but no anaplastic cells seen on smears. These patients have a benign seroma and do not need further workup and should be treated for a benign seroma. This has been done with antibiotics, implant exchanges and sometimes even a partial capsulectomy.

The FDA mandated CA/CARE Trial published in January 2017 by McGuire et al. was a prospective study of Biocell textured implants in 17,656 patients with almost 32,000 implants. The late seroma rate was 0.1% at 3.4 years. Common things being common, late seromas are likely to be benign, but they can be BIA-ALCL. In fact, in the CA/CARE study, 6 patients have BIA-ALCL or roughly 1 in 3,000 women in the study.

### Conclusions

BIA-ALCL cannot be diagnosed if plastic surgeons do not have a high index of suspicion in a patient who has a delayed seroma (>1 year after presentation). Specific testing of aspirated fluid needs to be performed to rule in or out the possibility of this rare disease process. To date, no case of BIA-ALCL have been reported in patients who have only had placement of smooth devices in their lifetime, either for augmentation or reconstruction. While the example provided here was in primary augmentation, delayed seromas can also present in revisionary augmentation and reconstruction procedures. We believe that by following these steps, patient safety in the diagnosis of BIA-ALCL can be improved.

### References

1. Clemens MW, et al. *Gland Surg* 2017;6:169-84
2. Personal communication, Dr Mark Clemens, May 2017.
3. NCCN Guidelines. Breast implant-associated ALCL Version 2.2017;
4. Adrada BE, et al. *Breast Cancer Res Treat* 2014;147:1-14;
5. McGuire P, et al. *Plast Reconstr Surg* 2017;139:1-9
6. Nava MB., et al. *Plast Reconstr Surg* 2018; 14(1);777e-779e

7. Clemens MW, et al. *Plast Reconstr Surg* 2018; 141(4); 586e-599e
8. Bridle CT, et al. *Aesthet Surg J* 2017; supplement 1-10
9. Srinivasa Dr, et al. *Plast Reconstr Surg* 2017; 139(5); 1029-1039
10. Hu H, et al. *Plast Reconstr Surg* 2016; 137 (6); 1659-1669
11. Adams, WP, et al. *Plast Reconstr Surg*; 2006; 117: 30-36
12. Giordano S., et al. *Aesthet Surg J*; 2013; 33: 675-680
13. Schwartz MR, et al. *Plast Reconstr Surg*; 140(1); 109e-114e
14. Adams, WP, *Plast Reconstr. Surg*; 2016; 137(6): 1670-1672

### Diagnostic Evaluation Based on NCCN Guidelines

Breast Implant Associated – Anaplastic Large Cell Lymphoma (BIA-ALCL) is a malignancy associated with breast implants that presents as a delayed seroma greater than 1 year after implantation. It can be seen in primary and revisionary breast augmentations as well as breast reconstructions. It can also present as a breast mass, and if so, should be worked up by a breast oncologist. When faced with a patient presenting with a delayed breast seroma, consider the following diagnostic evaluation based on NCCN guidelines:

1. **EDUCATE** the patient about existence and symptoms of BIA-ALCL during preoperative consultation and include in informed consent discussion.
2. **SUSPECT** the possibility of BIA-ALCL in patients with delayed seromas greater than one year from implantation, particularly those with a textured device implanted at some time in their history.
3. **PERFORM** a thorough physical examination including the contralateral breast and assessing for lymphadenopathy.
4. **IMAGE** the breast including regional lymph node basins with an ultrasound evaluating for fluid and/or mass.
5. **ASPIRATE** the fluid either in clinic or through interventional radiology. Place the fluid in a sterile specimen cup with NO FORMALIN. Send the specimen fresh for immediate evaluation. It can be refrigerated but after 3 days the specimen is no longer viable.
6. **SEND** the fluid for **CD30 immunohistochemistry** and **cell block cytology** and **aerobic** and **anaerobic cultures**.
7. **ASK** the pathologist to assess and rule out BIA-ALCL. If positive, the pathologist will further test for flow cytometry for a single T cell clone, as well as ALK translocation to differentiate BIA-ALCL from systemic ALCL. ALK translocation is negative in all cases of BIA-ALCL.
8. **DISCUSS** the diagnostic workup results with the patient, obtain a preoperative PET/CT scan for workup of systemic disease, and formulate a treatment plan.
9. **COORDINATE** next appropriate steps in management, with consideration for consultations to lymphoma oncology and surgical oncology to facilitate a multidisciplinary approach. Advanced cases may benefit from referral to a high volume tertiary cancer center.
10. **TREATMENT** with total capsulectomy, removal of implants, and excision of involved lymph nodes. Chemotherapy for advanced disease and radiation therapy for unresectable disease per NCCN guidelines.
11. **REPORT** all confirmed cases to the PROFILE registry, [www.thepsf.org/PROFILE](http://www.thepsf.org/PROFILE)
12. **FOLLOW** the patient closely and **ASK** for help from local or national experts on the treatment of BIA-ALCL when questions arise.

# WHAT IS GOOD PLASTIC SURGERY UNDER THE NORTHERN STAR?



**ASKO SALMI, MD**

Finland

Former ISAPS National Secretary for Finland

The poverty, ruggedness and harsh climate of the northern countries did not give rise to extravagant kingdoms with gold and exuberant ornaments. On the contrary, life was hard, simple and straight forward. Ostentation was vanity.

Given this background, it is not a surprise that functionalism in architecture in the 40's was accepted very easily - even eagerly - in Finland and other nordic countries. Alvar Aalto (1898-1976) was one of the most renowned architects of functionalism in Finland and abroad. The idea is simple: to create well functioning forms and spaces. This is the basis of the "Scandi Style" known all over the world.

In my country, the aesthetics of plastic surgery follow the principles of functionalism. Everything we do has to be nice - and hidden from the eyes of others. Too much is too much. The life of an aesthetic surgeon can be rewarding, but also very stressful and frustrating. In my opinion, the best reward for a job well done is a happy, pleased patient. Many publications show that aesthetic surgery not only fixes a physical problem, but also improves mental and social life. On the other hand, it is estimated that up to 13% of aesthetic surgery patients suffer from body dysmorphic disease so whatever you do, the result is not good enough and more surgery is demanded by the patient.

## WHAT IS GOOD SURGERY?

It is obvious that intra- or post-operative complications are not good surgery - as inevitable as they are and however much we try to avoid them. Surgical skills, patient selection, pre-, intra- and post-operative treatment must be of top quality - of course.

In aesthetic surgery, there is always a fear that the patient will not be satisfied after surgery. It is not enough that the surgeon is happy with the result. Happiness must be mutual - as in a good marriage. Thus it is clear that unrealistic expectations and merely imagined damage or faults cannot be operated on. There has to be mutual understanding in the same language meaning that the same words have the same meaning for both the surgeon and the patient. All languages have tens of thousands of words and even for native speakers, words can have different meanings or different grades of meaning - not to mention people from different cultures with different ideas about what they think is beautiful.

The concept of beauty is bound to your culture and your education. Most likely gender and age also affect your thoughts about this. In Finland, it is crucial that the results of any aesthetic surgery will not be obvious to anyone else. After surgery, you feel better about yourself and you gain new power for future challenges.

However, in many countries the opposite is true. Surgical results must be seen and it does not matter if the amount of money spent for surgery is visible. New breasts or a facelift worth a new premium car is something to be proud of and to be displayed to all. In Finland, this would be a catastrophe.

Under the northern star, results must be natural and long lasting. Of course, as plastic surgeons we must be aware that there is no such thing as time-stopping surgery or treatment. Time flies and aging goes on however we try to stop it. At best we can gain some more time of a youthful appearance.

It should be clear that a crucial part of aesthetic surgery is that it is well planned with as few visible scars as possible. Surgeons who operate without any resulting scars belong to the mythology of plastic surgery. Human beings are not machines in which fixing something is just engineering and with the same effort you can always count on the same result. Humans are individuals, so fixing the body is also individual and thus results are always a little bit different and unique to each patient. At the moment, we can't change the genome and even wound healing seems to be difficult to control.

It is almost as difficult to predict the future as to remember yesterday or the day before. However, thinking about the past gives us an idea of what will come in the future. Look at old pictures from the sixties or even the fifties. How long will these duck-like-lips and other masterpieces still walk among us? Not very long I suppose, and pictures from today will look funny after fifty years, too - if not sooner.

Aesthetic surgery under the northern star is skillful surgery performed on well selected patients and never too obvious.

It would be very interesting to hear from my colleagues all over the world about what is regarded as good aesthetic surgery and what patients expect when coming to a consultation.

# GDPR SURGEON'S GUIDE



## IVAR VAN HEIJNINGEN, MD

Belgium  
President, EASAPS  
Chair, ISAPS Membership Committee

GDPR is the revision to the European Union's Data Protection Directive (1995) and is seen as having far reaching implications due to an extended territorial scope and commitment to Data Subject rights. GDPR became law throughout the EU on the 25th of May 2018.

GDPR focuses on personal information that is specifically relevant to an individual referred to as the "Data Subject" in the regulation.

GDPR not only applies to organizations located within the EU, but it will also apply to organizations located outside of the EU if they process personal information (PI). It applies to all surgeons, hospitals and clinics processing and holding personal data of data subjects (patients/clients) residing in the European Union, regardless of your location.

## ROLES

An important aspect of GDPR is to understand the roles and the obligations of those roles as defined by the regulation. The regulation refers to information as data and categorizes the roles as follows:

**The Data Subject** - The individual to whom the personal data refers, e.g. a patient, or client.

**The Data Processor** - Any staff member who processes the personal data on behalf of the data controller, e.g. a Surgeon, Doctor, Ward sister, Nurse or any other clinical administrative staff.

**The Data Controller** - The person or persons who determine the purpose and the way personal data is to be processed at the hospital, clinic or surgery. A person must be identified within your organization to act as Data Controller.

## SIMPLE GUIDELINES FOR DOCTORS

1. Know what data you have and why you have it
2. Manage data in a structured way
3. Ensure you have consent and make sure that it is evidenced
4. Know what medium is the data stored on (Paper/Hard Drive/USB stick)
5. Encrypt any data that you wouldn't want to be disclosed
6. Design a security aware culture, store data securely
7. Know who is responsible for it (Data Controller)
8. Be prepared - expect the best but prepare for the worst (Breach control)

## Personal Data Classification

It is important to understand where personal information is held and that the Data Controller understands how the data is to be used. This is best accomplished by understanding personal data classification as follows:

**Personal Data** - means data that relates to a living individual who can be identified

By the person's birth date, the last four digits of National Insurance or other Social Security type number and name, credit card numbers with the cardholder's name, Tax ID or other identification card with name.

Or, from the data and other information which is in the possession of or is likely to come into the possession of the Data Controller.

**Sensitive Personal Data** - refers to information that is likely to cause emotional or possible physical harm and consisting of information as to:

- The racial or ethnic origin of the data subject.
- The data subject's political opinions.
- The data subject's religious beliefs or other beliefs of a similar nature.
- Whether the data subject is a member of a trade union or association.
- Their physical or mental health, medical conditions or history.
- The data subject's sexual life.
- The data subject's commission or alleged commission of any offence.
- Any proceedings for any offence committed or alleged to have been committed.

## SCOPE

GDPR provides clarity of responsibility and of commitment to the rights of the individual to whom the personal information belongs. GDPR clarifies relevance, particularly that a Data Controller never owns the personal data and that the Data Subject retains ownership of their personal data.

GDPR provides updates to the EU's DPA, the Data Protection Act (1998), specifically the following:

- **Increased Territorial Scope** - GDPR applies to all organizations processing the personal data of EU residents, regardless of that organization's location, or where that data is hosted.
- **Breach Notification** - Breach notification to the supervisory body (the Information Commissioner's Office (ICO) in the UK), and the known affected Data Subjects, will be mandatory in all member states where a data breach is likely to "result in a risk for the rights and freedoms of individuals." This must be issued within 72 hours of first having become aware of the breach. This includes notifying the Data Subjects.
- **Penalties** - A breach of the GDPR can incur significant fines, up to 4% of annual global turnover or €20 Million (whichever is greater).
- **Consent** - A request for consent to collect and retain personal data must be given in an intelligible and easily accessible form by the Data Controller or Data Processor to the Data Subject with the purpose of data processing attached to that consent using clear and plain language. It must be as easy to withdraw consent, as it is to give it.
- **Privacy by Design** - The Data Controller will include data protection from the outset when designing new systems, rather than as an optional extra.
- **Vendor Management** - It is the responsibility or organizations to comply with GDPR and they should provide evidence, either by assessment or other means, of clarification.

Continued on Page 12



## DATA SUBJECT RIGHTS

Beyond seeking specific consent to use the Data Subject's personal information, there are further rights extended to the Data Subject by the Data Controller as follows:

- **Right to Access** – The Data Subject must be able to obtain from the Data Controller confirmation as to whether personal data concerning them is being processed, where, and for what purpose.
- **Right to Rectification** – When a Data Subject's data is found to be incorrect, or incomplete, the Data Subject can request that it is corrected.
- **Right to be Forgotten** - The right to be forgotten entitles the Data Subject to have the Data Controller erase his or her personal data, removing all instances.
- **Data Portability** - A Data Subject can request and receive the personal data concerning them in an easily readable format and have the right to transmit that data to another controller.
- **Right to Object** – The Data Subject has the right to remove consent to the processing of their data at any time. Also included are Rights regarding restrictions of processing personal data and the ability to request intervention by a human where machines undertake automated processing.

## GOVERNANCE

GDPR specifies the responsibilities of each organization maintaining a GDPR point of contact, the Data Protection Officer (DPO). The DPO is central to establishing and maintaining the core responsibilities of organization compliance. The regulation states that the DPO can be a member of staff or a trusted third party, not dictating that it be a full-time role, and only mandatory in certain circumstances (see below).

GDPR specifies mandatory requirements of a Data Protection Officer in the following instances:

- Public authorities.
- Organizations that perform large scale systemic monitoring of individuals.
- Organizations that perform large scale processing of special categories of data or data relating to criminal convictions and offences.

GDPR outlines the duties of the Data Protection Officer as follows:

- To inform and advise the organization and its employees about the obligation under GDPR and other data protection laws that the organization may be subject to.
- To monitor compliance with the GDPR and other data protection laws, including;
  - Managing internal data protection activities.
  - Advising on data protection impact assessments.
  - Training staff and conducting internal audits.
- To be the first point of contact for the supervisory authorities and for the individuals whose data is processed (employees, customers).

## FAQ'S

- Q. Does the normal confidentiality obligation between Doctor/Surgeon and their patient apply?**  
 Normal obligations do apply, but you will need to obtain written consent from your patient. If you do not already have a signed agreement, then it would be best to have one in place.

- Q. Can a patient request to change personal data when that is convenient for them?**

The *GDPR* includes a right for individuals to have inaccurate personal data *rectified* or completed if it is incomplete. An individual can make a request for *rectification* verbally or in writing. You have one calendar month to respond to a request. In certain circumstances, you can refuse a request for *rectification*.

You can refuse to comply with a request for rectification if the request is manifestly unfounded or excessive; consider whether the request is repetitive in nature. If you consider that a request is manifestly unfounded or excessive you can:

- request a “reasonable fee” to deal with the request; you should base the reasonable fee on the administrative costs of complying with the request. If you decide to charge a fee, you should contact the individual without undue delay and within one month. You do not need to comply with the request until you have received the fee.
- or refuse to deal with the request.
- In either case you will need to justify your decision.

- Q. Can a patient ask to delete their patient record?**

It would be justifiable to retain information. Ideally this should be covered within the consent. GDPR does not override any prior or new “legal” obligation.

- Q. If a patient is sexually active and has a high risk of STD's, can such a patient ask to remove that information?**

If they have agreed to the collection of their information, and it is relevant to the patient and that the risk of infection is real to the Doctor and/or third parties, the Doctor should keep the information; however, as you would expect, it cannot be disclosed, shared or transmitted as it is classed as secret personal data.

- Q. Do I need to appoint a Data Controller when my surgery consists of a Doctor and a member of support staff?**

The answer is no, you do not have to appoint a Data Controller; however, you must appoint (identify) some person who is responsible for managing patient's data.

- Q. Due to the new GDPR regulations are we obliged to destroy all data after this retaining period or not?**

GDPR does not override any prior or new “legal” obligation. Therefore, you do not need to destroy patient information although, and where possible, it is advisable that you obtain written consent from your patients.

The overriding and clear message of this legislation is that in the first instance the data controller (the doctor or office/practice manager) must provide assurance of data security. There are instances where a Doctor can overrule GDPR if there are legal or moral reasons pertinent to that country.

**Please do not forget that if you are ever challenged, you must always obtain legal advice.**

**It is always advisable to take independent legal advice as this document is merely a guide to the possible implications of GDPR.**

# ISAPS PRIVACY POLICY

The new ISAPS Privacy Policy became effective on May 1, 2018.  
*We wrote this policy to help you understand what information we collect,  
how we use it and what choices you have.*

We collect information in a few different ways:

## 1. When you give it to us or give us permission to obtain it

When you join ISAPS as a member, pay dues, purchase a membership plaque or attend any of our meetings, you give us your information voluntarily. This may include your name, work address, home address, email address, phone numbers (work, fax, cell, home), profile photo, date of birth and payment information. If you purchase a plaque and have it sent to an address other than your own, we collect the delivery details and contact information.

If you link your Facebook or Google account or accounts from other third-party services to ISAPS, we may also get information from those accounts. The information we obtain from those services depends on your own settings and their privacy policies, so please be sure you understand them clearly.

## 2. We also get technical information when you use the ISAPS website, ISAPS Congress website, online registration program, Congress website chat area, abstract submission program and when surveys are sent to you.

Whenever you use any website, mobile application or other internet service, certain information is created and logged automatically. The same is true when you use ISAPS sites.

Here are some of the types of information we collect:

- **Log data.** When you use ISAPS websites, our servers record information ("log data"), including information that your browser automatically sends whenever you visit a website, or that your mobile app automatically sends when you're using it. This log data includes your Internet Protocol (IP) address, the address of and activity on websites you visit that incorporate ISAPS features.
- **Cookie data.** We also use "cookies" (small text files sent by your computer each time you visit our website, unique to your ISAPS account or your browser) or similar technologies to capture log data. When we use cookies or other similar technologies, we use session cookies (that last until you close your browser) or persistent cookies (that last until you or your browser delete them). Some of the cookies we use are associated with your ISAPS account (including information about you, such as the email address you gave us) and other cookies are not.
- **Device information.** In addition to log data, we collect information about the device you use to access the ISAPS websites, including type of device, operating system, settings, unique device identifiers and crash data that helps us understand when something breaks. Whether we collect some or all of this information often depends on what type of device you are using and its settings. For example, different types of information are available depending on whether you use a Mac or a PC, or an iPhone or Android phone. To learn more about what information your device makes available to us, please also check the policies of your device manufacturer or software provider.

## TECHNICAL INFORMATION WE COLLECT WHEN YOU USE OUR INFORMATION TOOLS

- Usage data and preferences
  - Sign-up data
  - Authentication detail
  - Login history

- Session log - Actions taken during a session
- Device specific information (device type and identifiers; events, such as crashes)
- Account profile information
- Cookies associated with your account
  - Verifying your login credentials
  - Pages you view and actions taken on sites or with browsers incorporating ISAPS information

## What we do with the info we collect:

- We use the information we collect to provide ISAPS services to you. We commit to showing you content that's relevant, interesting and personal to you. In order to do that, it's necessary for us to use your information to:
  - Identify you when you use the ISAPS websites, and process your transactions for registrations, dues payments and plaque orders.
  - Respond to your questions or comments.
- We also have a legitimate interest to improve the ISAPS website, maintain our relationship with you, and protect users. We both benefit when we use your information to:
  - Help your patients and contacts find you on the ISAPS website, if you agree to this.
  - Conduct analytics on who is using the ISAPS websites and what they are doing.
  - Improve ISAPS websites and offer new features.
- In addition to the specific circumstances above, we'll only use your information with your consent to send you ISAPS informational materials by mail, and email depending on your account or operating system settings.

Each time we send you an informational email, we give you the option to unsubscribe.

## Transferring your information:

ISAPS is a worldwide organization. By using the ISAPS websites, you authorize us to transfer and store your information outside your home country for the purposes described in this policy. The privacy protections and the rights of authorities to access your information in these countries may not be the same as in your home country.

## Choices you have about your info:

Our goal is to give you simple and meaningful choices regarding your information. If you are an ISAPS member, or applying for membership, many of the choices you have with ISAPS are built directly into the ISAPS website or your settings. For example, you can:

- Edit information posted on the website by contacting the Executive Office at any time, decide whether your profile is available on the ISAPS website.
- Withdraw your ISAPS membership at any time. When you do this, we will remove your information from the ISAPS website.

Continued on Page 14

## ISAPS PRIVACY CONTINUED

---

You also have choices available to you through the device or software you use to access the ISAPS website. For example:

- The browser you use lets you control cookies or other types of local data storage.
- Your mobile device lets you choose how and whether your location, photos, advertising identifiers and other data is shared with us.

To learn more about these choices, please see the information provided by your device or software provider.

### How and when we share information:

- Anyone can see your information on the ISAPS website – name, address, phone number, email address. Some of the ways we use your information requires us to share information with third parties, so we can provide you with an exceptional ISAPS experience, make sure our customization is effective and that it complies with laws that apply to us. We share your information with:
  - Other services (like Facebook or Google) when you decide to link your ISAPS account to those services or publish your activity on Facebook.
  - Online advertisers and third-party companies that we or they use to audit or improve the delivery and performance of ads or content on websites and apps (for example, through Google Analytics). This includes what website pages you visited and whether or how you engaged with those pages, or other information about your activity on any ISAPS websites.
  - Third party companies or individuals that we employ to process information on our behalf based on our instructions and in compliance with this Privacy Policy. For example, we share payment card information with the payment companies we use to store your payment information. We also share data with security consultants to help us get better at identifying spam. Some information we acquire may be collected by third party providers on our behalf. Our website developer has access to your data in order to include it on the website.

### How long we keep your information:

- We keep your information for five years after your membership lapses or after an event such as a course or congress has ended.

### Your options:

You have options in relation to the information that we have about you described below. To exercise these options, please contact us. You can:

- Have your information corrected or deleted. You can update your information by contacting us.
- Object to us processing your information. You can ask us to stop using your information, including when we use your information to send you marketing emails. If you opt out of receiving marketing messages from us, we may still send you newsletters and updates about upcoming events. We only send you marketing material if you've agreed to it, but if you'd rather we don't, you can easily unsubscribe at any time.
- Complain to a regulator. If you're based in the EEA and think that we haven't complied with data protection laws, you have a right to lodge a complaint with the Data Protection Commission or with your local supervisory authority.

## CONTACTING US

If you have any questions regarding the privacy policy, the best way to contact us is:

Tel 1-603-643-2325

Email [ISAPS@isaps.org](mailto:ISAPS@isaps.org)

Mail ISAPS Executive Office  
45 Lyme Road, Suite 304  
Hanover, NH 03755, USA

The ISAPS Executive Office is responsible for protecting your information.

## VAN HEIJNINGEN CONTINUED

---

### TO DO'S

Some steps you should take to protect yourself now.

1. Make sure that your staff are aware of the implications of GDPR as well as how to handle data. You should document what personal data you hold, where it came from and who you share it with. You may need to organize an information audit.
2. You should review how you seek, record and manage consent and whether you need to make any changes.
3. Appoint a Data Controller. If you are a small surgery/practice, this could be the person who manages your facility (Practice Manager) or the Doctor/Surgeon who runs the practice.
4. If your facility handles information regarding patients travelling from another EU member state, you should determine your lead data protection supervisory authority.
5. You should make sure you have the right procedures in place to detect and report a personal data breach.

Finally, the potential fines are substantial and could be ruinous for a small company or practice. It is therefore imperative to have proper processes, procedures, policies and insurances in place.



# MESSAGE FROM THE EDUCATION COUNCIL



**VAKIS KONTOES, MD, PHD**  
Greece  
Chair, ISAPS Education Council

Our news from the Education Council (EC) is more and more exciting every time we report to you. The demand for educational events worldwide is steadily growing and we are happy to promote our education mission at high standards around the globe. The work involved in organizing our Biennial Congress in Miami Beach on October 31 to November 4 is at its peak and we are convinced this is going to be a landmark event for ISAPS.

The deadline for abstract submission expired on the 18th of April and a new historical record was achieved! We received a total of 555 papers and accepted 379 filling all available Free Paper speaking slots. Each presenter will have 10 minutes, with 8 minutes for presentation and 2 minutes for discussion. We encourage you to attend those sessions on topics that interest you to encourage our young presenters in particular.

Thank you to those members of the EC and the many National Secretaries who participated in scoring abstracts. This represents a great deal of work, but it is important and we appreciate the time you spent to help us evaluate the submissions. The EC invited the National Secretaries for the first time ever to review submitted papers for our biennial Congress and we are very proud to have involved them in this interesting scientific task.

The ISAPS Video Library, which is steadily growing in topics and gradually enriched with video clips of several aesthetic surgery techniques, is open and available to our ISAPS members on the website. The provision of quarterly live surgery webinars is booming and all our members will benefit from this exciting new educational “product.”

Very interesting educational events were organized in the last three months and are in the planning phase for future months.

On March 9-10, an **ISAPS Course**, a first-time event for Spain, took place in **Barcelona**. High attendance and excellent organization provided the participants with high-standard information on patient safety and complications related to aesthetic surgery procedures. The talks and long panel discussions of this outstanding meeting were recorded in high definition videos and will soon be uploaded to our Video Library and available to all our members for the benefit of their practice and patients.

In April, an **ISAPS Symposium** held in cooperation with the Korean Society of Aesthetic Plastic Surgery – another “first” – was organized in **Seoul, South Korea**. It was a very successful event that brought ISAPS and the Korean Society closer together.

The **Saudi Arabia ISAPS Symposium** in **Riyadh** was another extremely successful educational event. A large number of attendees, high-class organization and outstanding presentations with CME credits made this “first” ISAPS event in this country another great success.

At the end of May, in cooperation with SOFCEP, the annual **ISAPS/SOFCEP Symposium** was held in **Lyon, France** with a great faculty and interesting topics on aesthetic surgery procedures.

The **Bali ISAPS Symposium**, in co-operation with OSAPS and InaPRAS, will be organized on the 18th and 21st of July.

A new **ISAPS Symposium in Chile** preceding the annual meeting of Chilean Society will be organized on the 27th and 28th of July in Santiago.

ISAPS EC and Board are very proud of the **ISAPS in Rio** meeting on August 1-4 and another Course in **Porto Alegre** in September - two landmark educational events in Brazil. We sincerely thank our Local Brazilian Organizers for their great contribution to the ISAPS education mission.

An ISAPS endorsed live surgery meeting in **Monaco** will be realized on September 20-22 this year with a lot of hands-on interaction with the participants.

New educational events were approved by the EC in **Vietnam** in December 2018 and **Egypt** in February 2019. And more are coming soon!

Information and details about upcoming ISAPS educational events are always available on the ISAPS Calendar in our website under the heading Medical Professionals.

The Education Council has also endorsed many aesthetic surgery meetings for 2018 and 2019. A steadily increasing rate of endorsement applications was received in the last 12 months. This shows the appreciation by the organizers of the ISAPS brand and dedication to our mission: *Aesthetic Education Worldwide®*. The EC cordially acknowledges the local organizers of the endorsed meetings for their cooperation with ISAPS.

Thank you all for your support and stay tuned for more exciting ISAPS educational projects that continue to improve and reach amazing standards worldwide.

# THE INTERNATIONAL CONGRESS OF PLASTIC SURGERY AND AESTHETIC MEDICINE - UKRAINE 2018: CELEBRATE DIVERSITY



**BRYAN MENDELSON, MD**

Australia  
ISAPS Past President

It gives me pleasure to report on the International Congress of Plastic Surgery and Aesthetic Medicine (ICAMPS) that was held in Kiev, Ukraine on March 16-17, in which I participated representing ISAPS. This was an excellent meeting, organized by the ISAPS National Secretary for Ukraine, Pavlo Denyshchuk, whose contributions have raised international awareness of aesthetic surgery in



Figure 1 - Pavlo Denyshchuk, founder of ICAMPS, ISAPS National Secretary, with the headliner of the congress Bryan Mendelson.

Ukraine. He previously brought renowned ISAPS faculty to Kiev on several occasions. This meeting was different, being a stand-alone event separate from the national meeting and consisting of two concurrent parts. Alongside the plastic surgery meeting was a cosmetology and dermatology, non-surgical meeting, that provided significant and worthwhile

crossover. The surgical meeting comprised of international faculty coming from Australia (myself), USA, the ever-creative Claude Le Louarn from Paris, other aesthetic surgeons from non-plastic surgical backgrounds, and surgeons mainly from Europe. It added considerable interest to have speakers from different specialties and with somewhat different perspectives.

The diverse content of this meeting thoughtfully included many aspects of practice, particularly on overall patient selection and care. The especially important part of this training were the live surgery and cosmetology workshops that were performed during the two days of the congress. Facial anatomy was thoroughly reviewed in the theoretical part of both surgical and cosmetology sessions and a great deal of time was devoted to the complications that are



Figure 2 - "Warm atmosphere and incredibly white snow," - Claude Le Louarn, visiting Ukraine for the first time, shared his impressions.

common for surgeons' and cosmetologists' practices. Speakers shared their experience in managing, avoiding and treating complications that they had faced in their practice.

There were 151 plastic surgeons and 128 dermatologists and cosmetologists attending who came from Ukraine, surrounding former Soviet countries, EU countries and even the Middle East. Common theoretical and practical training for plastic surgeons and

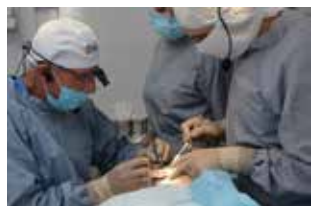

Figure 3 - The operation viewed by 150 surgeons from 12 countries - Bryan Mendelson reveals the method of SPACE-lifting.

cosmetologists enriched all the participants with new experiences. It is important to note that cosmetologists had a great interest in the reports presented by the plastic surgery speakers especially by specialists in aesthetic medicine. This gave an opportunity for everyone to learn something new: new methods, new approaches, new ideas – and of course inspiration.



Figure 4 - Gala-Dinner with a flair: Ukrainian culture in the performance of the famous chorus named after H. Veryovka.

The meeting was superbly organized with excellent administration and attention to detail with the outstanding facilities in the Conference Centre of the beautiful Intercontinental Hotel. What impressed me most was the wonderful support staff present at all times, the unusually good refreshments during the breaks and the excellent social

functions. No details were overlooked. Aside from this, my memory is of the friendliness of the attendees, as well as all the people in Kiev whom I met, and the gratitude of the attendees for the teaching provided for them right on their own doorstep. Of course, this success was provided particularly through the commitment of Pavlo Denyshchuk and his loyal team, with the strong support of the Ukraine National Society with President Vasyl Khrpach, a major contributor to the conference.

Like many people, I had reservations about the safety of the region because of the media reports about civil unrest and outside interference in Ukraine. However, there was not the slightest evidence of this and I can thoroughly recommend to colleagues to visit Kiev. It is a stylish city with remarkable historical sense and lovely parks and grand buildings that were all covered with snow during the week of the meeting, contrasting many conspicuously gold dome cathedrals. Since the 1991 separation from the Soviet Union, Ukraine is emerging with the energy of a new nation enjoying freedom and independence in seeking its own identity, all with the benefit of an extraordinary history.

I would rate this visit as a privilege and one of the highlights of my official functions representing ISAPS and I thank fellow faculty with whom I shared many good times and interesting discussions, and the participants for their appreciation of this learning opportunity, their enthusiasm and their readiness to ask questions. This experience caused me to reflect on the importance of ISAPS to our colleagues in ISAPS affiliated societies, many of whom have limited opportunity to attend international courses. All ISAPS members should be proud of the outreach aspects of our Society which has a large and diverse faculty. ISAPS is certainly fulfilling its adopted role of *Aesthetic Education Worldwide*®.

# ISAPS OFFICIAL COURSE CAPE TOWN, 23-25 MARCH 2018



**PETER SCOTT, MD**  
South Africa  
ISAPS National Secretary for South Africa

Ewa Siolo and I had the pleasure of hosting an extremely successful ISAPS Official Course in Cape Town at the end of March. The venue was in the heart of the winelands at the Lord Charles Hotel. Our International Chairman was Vakis Kontoes, Chair of the ISAPS Education Council and the program covered the full spectrum of surgical and non-surgical aesthetic procedures. The twelve international faculty included Vakis Kontoes (Greece), Nimrod Friedman (Israel), Gianluca Campiglio (Italy), Alexander Dionyssopoulos (UAE), Morris Ritz and Tim Papadopoulos (Australia), Bertha Torres-Gomez and Arturo Ramirez-Montanana (Mexico), Dana Jianu (Romania), Frank Elliott (USA), Jan Fabre (Netherlands) and Marshall Murdoch (South Africa).



Figure 1 - Drs. Peter Scott, Gianluca Campiglio and Vakis Kontoes.

We had 160 delegates including most of the active South African plastic surgeons and a number of International visitors. The lectures were extremely well attended even up to the final lecture on the last day. The faculty, who have lectured together on many occasions, provided lively discussion and interactive panels.

On the social side, the faculty met the night before the Congress at Henri's, a popular local bistro, for a meet-and-greet followed by a cocktail party the first night of the meeting where local delegates were able to interact with them. The faculty dinner was a highlight with a surprise performance by two local singers who had everyone up and dancing and ending with the song *We Are Family* which epitomizes the spirit of ISAPS. The last event on the social program was an informal steakhouse dinner to allow the faculty to catch their breath and socialise on an informal basis.



Figure 2 - Faculty members Bertha Torres, Ewa Siolo and Dana Jianu.

The faculty wives and one husband were treated to a very active program visiting vineyards, sculpture gardens, local craft markets and small informal lunches as well as visits to the iconic Table Mountain and Cape Point.



Figure 5 - On-site course registrants.

Most of the faculty departed for a three-day safari at Thornybush Game Lodge which is a Big Five game reserve. We had wonderful sightings, in particular an angry hippo, placid rhinos, curious elephants, a sleeping lion and a leopard up in a tree. Included in the safari were a bush breakfast and a wonderful dinner in the bush by lantern light with a three-quarter moon.



Figure 3 - Drs. Alexander Dionyssopoulos, Arturo Ramirez-Montana, Peter Scott, Tim Papadopoulos, Vakis Kontoes and Anthony Geroulis.



Figure 4 - Eugenia Dionyssopoulos, Debra Fletcher, Bertha Torres, Sue Scott, Denise Kontoes, Maria Papadopolous and Dana Jianu.

Lifelong friendships were forged and all indications from the local delegates were that this was the best ISAPS event that they have attended. All of our faculty members marketed ISAPS Miami 2018 actively and Vakis Kontoes showed the video on two occasions as well as the PowerPoint presentation about ISAPS.



# ISAPS OFFICIAL COURSE: BARCELONA



**JESUS BENITO-RUIZ, MD, PHD**  
Spain  
ISAPS National Secretary for Spain

In Barcelona, within the framework of the Education Council of the International Society of Aesthetic Plastic Surgery, we organized a course dedicated exclusively to patient safety and prevention of complications. It is an extraordinarily important topic in any surgery, but even more in an elective treatment when the patient decides to undergo this intervention.

The Director of the Course was Dr. Vakis Kontoes (Greece), ISAPS Education Council Chair, Co-Director was, Dr. Ivar van Heijningen (Belgium), EC Local Representative for Europe and as President of the Spanish Association of Aesthetic and Plastic Surgery (AECEP), I served as the Local Chair.

Our esteemed faculty included Drs. Mario Pelle Ceravolo (Italy), Jim Grotting (USA), Mark Clemens (USA), Kai Kaye (Spain), Jorge Bayter (Anesthesiologist, Colombia), David Lumenta (Austria), Marisa Manzano (Spain), Arturo Ramirez-Montañana (Mexico) and Bertha Torres (Mexico). On the part of the insurance companies, Ms. Alison Thornberry (UK) from ISAPS Insurance and Ms. Cristina Sánchez, lawyer of AMA, the main Spanish association for civil responsibility of plastic surgeons in Spain.



Figure 1 - Panelists Drs. Vakis Kontoes, Arturo Ramirez-Montañana, James Grotting and Mario Pelle-Ceravolo.

It was a very interesting and educational event and we all learned a lot about how to keep our patients safe before, during and after surgery.

The main topics addressed were:

- Patient selection: determine if the patient is in adequate physical condition and their expectations can be met depending on the current state of the surgical techniques and the surgeon's preparation.
- Prevention of bleeding, post-surgical anemia and reduction of the need for transfusions.
- Prevention of deep vein thrombosis and pulmonary embolism. Risk must be stratified (Caprini) in order to indicate the appropriate prophylaxis in each case. Cosmetic surgery is not exempt from that risk. In fact, abdominoplasty, post-bariatric surgery and the combination of procedures, especially breast and abdomen, are the most at risk.

- Prevention of hypothermia that occurs in the operating room under general anesthesia and that is causing a worse experience of the process by the patient (chills and shivering in the post-anesthetic recovery) and increased risk of bleeding and hematoma.
- Determine the best policy regarding the use of antibiotics: when and how to perform prophylaxis and determine if it is necessary to continue with antibiotics after surgery. Precisely it has to be consistent with the global policy on use of antibiotics. Misuse increases resistance and reduces the effectiveness when they are really necessary.
- The fate of bacteria in the breast, texturization of implants and consequences on capsular contracture and ALCL.
- Safety in buttocks fat grafting, a procedure that has been involved in several deaths in South America and the United States. It can be a safe procedure if the anatomical characteristics of the region are taken into account.
- Prevention and treatment of complications in facial aesthetic surgery procedures such as face-lift and blepharoplasty, breast surgery and rhinoplasty.

We also talked about informed consent, insurance coverage in case of complications and the protocols that have to be followed by a center where an operating room for ambulatory surgery is located.

A very important and well appreciated issue during this Course was the long discussions that followed each panel among the speakers and the audience, with plenty of different views on safety procedures and in depth analysis of several complications in aesthetic surgery.



Faculty - Front row: Vakis Kontoes, Arturo Ramirez-Montañana, Bertha Torres, James Grotting, Mario Pelle-Ceravolo, Marisa Manzano. Back row: Joan Fontdevila, Kai Kaye, Mark Clemens, Jorge Bayter, Ivar van Heijningen, Jesus Benito-Ruiz.

# FOURTH ANNUAL CONFERENCE IN PANAMA



**LUIS A. PICARD-AMI JR, MD, FRCSC, FACS**  
Panama

The 2018 conference, *Highlights of Plastic Surgery*, held on March 15-17 was our fourth consecutive meeting and it will continue to be an annual event. Next year the dates will be March 14-16, 2019. Last year, we had 6 international speakers and 220 registered plastic surgeons. This year we had 16 speakers and over 190 plastic surgeons attended. Our speakers came from Japan, Sweden, Germany, the United States, México, Costa Rica and Chile.

The three-day format included one day for breast surgery, one day for facial surgery and one day for body contouring. This year was unique in that we had a patient safety workshop directed by Dr. Lazaro Cardenas, President of the Mexican Society of Plastic Surgery and Dr. Jorge Bayter, an anesthesiologist from Colombia who has written several books and led many patient safety workshops around the world. In addition to the plastic surgeons, over 30 of our local anesthesiologists attended and actively participated in this interactive workshop stressing the team approach for preventing and managing catastrophes that often lead to fatal results in the operating room.



Figure 1 - Dr. Luis Picard Ami and Dr. Luis Crespo, meeting organizers, with Dr. Renato Saltz President of ISAPS.



As in previous years, the registered plastic surgeons came from almost all the countries in Latin America, but for the first time we also had several from the US, Canada and as far away as France.

The ISAPS Miami Congress brochures arrived on time and were well distributed in all the individual handbags as well as throughout the conference.

Figure 2 - Dr. Julian Pribaz giving a lecture on Facial Transplants.



Figure 3 - Drs. Arturo Ramirez-Montañana from Mexico, Johan Nordquist from Sweden and Neil Fine from Chicago enjoying one of the evening events with Panamanian Folkloric dancers and Carnival Queens.

## GUESS WHO?



See page 38 for the answer

## WHERE IN THE WORLD?



See page 57 for the answer

# GLOBAL ACCREDITATION UPDATE



**OZAN SOZER, MD**  
United States  
Co-Chair, ISAPS Global Accreditation Committee  
Vice Chair, ISAPS Education Council

The global accreditation committee has been working to prepare rules and regulations for a safe surgery center that will be applicable throughout the world. We have recently completed the full set of regulations that will be divided into three groups: Basic, Intermediate, and Advanced. We will prepare a booklet before the Miami 2018 Congress to be distributed to our members there.

We will also start looking into ways to offer credentialing in different parts of the world. We will be consulting our Global Alliance members to get their input in the near future.

ISAPS truly believes in patient safety throughout the world and we hope to have a structured plan to be presented during the Congress in Miami Beach.

## ISAPS WOULD LIKE TO OFFICIALLY THANK AND ACKNOWLEDGE THE GENEROUS SUPPORT OF OUR GLOBAL SPONSORS

<b>ISAPS Premier Global Sponsor Program</b>		<b>POLYTECH</b> health & aesthetics 
		 NORTH AMERICA
		 Motiva <sup>®</sup> implants
		 NeoGraft <sup>®</sup> A Division of Venus Concept

Introducing from the MotivaEdge our new educational platform for breast surgery:

**THE SCIENCE <sup>OF</sup>  
BREAST TISSUE  
MANAGEMENT**

We deliver world class education and surgical training on the safe and effective use of our products by board certified plastic surgeons. Our mission, **Safety Through Innovation.**

Highlights include:

- Understand the science of implant surfaces and inflammation, rheology, tribology, and their impact on decision making and outcomes.
- Evaluate advanced techniques for breast surgery utilizing Motiva Implants: Motiva Ergonomix, MotivaHybrid, Motiva MinimalScars.
- Assess treatment options for breast augmentation and revision using proven surgical planning with our Divina 3D technology.
- Discuss prevention and management of possible complications arising during and after breast implant surgery.
- Analyze complex and challenging issues with faculty and peers.



Dr Del Vecchio



Dr Chacón



Dr Corduff



Dr Hammond



Dr Hedén



Dr Kinney



Dr Sforza



Dr Randquist



Dr Munhoz



Dr Nordquist



Dr Park

Join our world class faculty at one of our premium educational events in 2018:

Paris - Melbourne - Panama - Madrid - Sao Paulo - Tokyo - Stockholm - Saint Petersburg - Lago di Garda - Seoul

For more information contact us at: [education@motivaedge.com](mailto:education@motivaedge.com)



# MY THIRD MISSION IN TOGO



**ADRIANA POZZI, MD**

Italy

ISAPS National Secretary for Italy

This time I left alone. The Air France pilots' strike caused a one-day delay in the departure of my friends: Marie Christine, a Parisian who works as a volunteer and takes care of international diplomatic relations for associations like our AICPE Onlus, and Roberto, a Resident in maxillo- facial surgery whom I still had to meet personally.

During the flight, which stops at Niamey airport, I saw the barren land of Niger, a desert and desolate land, and I thought, "Who will ever stop in Niger?" However, after about an hour and a half, to my amazement, many people got off the plane and just over half the passengers remained on the aircraft.

Niger is a really huge country in comparison with Togo which is a strip of land facing the sea in the shape of a stick. In Italy, there are cookies covered with chocolate called Togo. Landing in Lome, the capital, looking out of the window, the comparison with the landscape seen one hour before was inevitable. Dense vegetation led to the turquoise sea and the bare soil was red.

Waiting for the hospital bus, with my heavy luggage by my side, I was immersed in the typical cheerful Togolese atmosphere of the city. A hot, damp wind comforted my weariness. A driver who had offered me a ride very kindly gave me the password to connect to the local wi-fi to give me the chance to send a reassuring message to my family. The bus driver sent by the hospital arrived two and a half hours later.



Figure 1 - Our driver stopped at a stand where gasoline is sold in large demijohns.

After finally getting on the bus, on the road to Afagnan, I understood why the driver was so late. He kept stopping to do the shopping at wooden stalls along the way where the vendors - usually a family consisting of mother, father, and their children - sell Togolese specialties, directly from their land, or even packaged commercial products of various kinds. Although the road to Afagnan, more than 80km away, has been resurfaced by the Chinese, the time to get to the hospital requires two hours of normal traveling, plus at least 30-40 minutes, if the driver has to go shopping for himself or for friars and nuns or even refuel at the Togolese distributor - another stand where gasoline is sold in recycled plastic

or glass liter bottles, or in large demijohns. And you can count yourself lucky if the Togolese driver has already eaten. Otherwise, there will be a further stop where he will buy just-made corn on the cob or fruit, which he will eat during the journey. On the way to the hospital, my driver bought an apple, which he did not eat during the trip, but which he placed on the dashboard of the bus. Every time he braked the apple fell under his feet and this was repeated six or seven times until I told him that maybe it was more prudent for me to keep the apple in my hand during the trip. As soon as we arrived at the hospital San Jean De Dieu, I returned the apple to the driver and got off with my luggage in front of the Cooperators' house.

During my first day of mission I examined several people: adults and children. Some of them had their operations planned during my mission, other more complex cases had to be planned for the larger mission next August.

My patients were children with keloid lesions, numerous severe burn sequelae. A big lipoma of the cheek of a 3-year-old girl that was not so easy to remove because it was very widespread. In Togo, clinical cases are never simple. Patients always arrive very late, when diseases are advanced and there is no prevention. There is no chance to make a histological exam and often we take the samples back to Italy.

There are no burn care centers. A sense of impotence afflicts me every time because patients often need many staged reconstructive procedures and often they do not come back to continue their therapy. Many skin grafts are lost because of infectious complications. Our AICPE Onlus pays for the operations for the poorest patients.



Figure 2 - Dr. Pozzi with a little boy whose nose has been reconstructed after a bite by a wild dog.

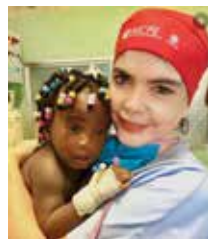

Figure 3 - Dr. Pozzi with a little girl suffering from cleft lip.

On the second day, my young mission partner arrived and together we could accelerate the operating room work. Also, Marie Christine started teaching French "a la petite école," the small school of the hospital's pediatric department, where mums also enjoy her funny lessons.

The hospital's operating room is very unconventional. Every morning our work day starts with a charming ritual, a prayer for "good work" followed by all the staff joining hands and walking around in a circle whilst thanking God for blessing their work. The majority of

people in Togo are Catholic and very devout. Some staff nurses were raised by Italian friars and speak Italian.

During the twelve days of our mission, the President of Togo, in order to win the people's sympathy, gave the population an unplanned day of vacation. In Togo, the government is dictatorial and in this period there are revolts against the regime so we took the opportunity to carry out an exceptional diplomatic mission in the state of Benin, where Marie Christine and I went, accompanied by Tekpone, a friend of hers and an advisor to the Benin President. This allowed us to guarantee cohesion to a Mission we had started last year at the Hospital of Abomey and to which we could not return this year due to a health problem of our President, Marco Stabile. But, thanks to our visit, the mission will continue regularly next year.

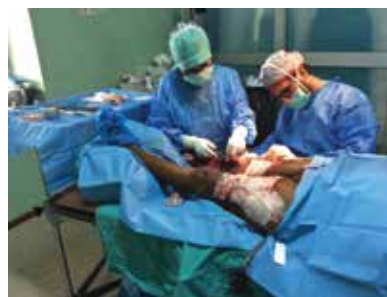

Figure 4 - Dr. Pozzi working with a young colleague.

As usual, our last mission day was very busy. From the morning till the early afternoon, we had scheduled surgery before departing for the airport in the late afternoon. Before our departure, our friends, nurses, nuns and friars, came to say goodbye and to thank us for our work. They are all always very grateful and this is what comforts us. The thought that comes to mind is this: who is helping whom?

# ISAPS EXPANDING HUMANITARIAN PROGRAM



**NINA NAIDU, MD**

USA

ISAPS National Secretary for the United States  
Chair, ISAPS Women Surgeons' Committee

On April 30, during the annual meeting of the American Society for Aesthetic Plastic Surgery (ASAPS) in New York City, our Executive Director Catherine Foss and nine ISAPS members met to discuss the future of the humanitarian arm within our organization. Between October 2013 and January 2017, ISAPS members participated in 18 relief missions to Amman, Jordan to help local surgeons treat injured Syrian refugees. A total of 450 patient evaluations and 263 surgeries were performed. An additional 25 trips were made to Jordan, Turkey, and Lebanon with the LEAP organization during which 907 patient evaluations and 438 surgeries were performed.

Our collaboration with the LEAP Foundation ended last year secondary to staff changes within their organization and increasing difficulty with national authorities in allowing foreign surgeons to enter the country to assist in various disaster relief efforts.

The discussion at the New York meeting therefore centered on how to best organize our many members who have expressed an interest in performing humanitarian work in countries where our help is most needed. There are two ways that plastic surgeons have traditionally provided care in other countries: the first is through short-term disaster relief missions as we did with the ISAPS-LEAP *Surgical Relief Teams*®, and the second is through ongoing care of routine cases, such as cleft lips and palates. While the former scenario allows us to treat a large number of patients who urgently need help following natural disasters or near war zones, it does require flexibility on the part of our members, and a well-established logistics team. The second scenario allows surgeons to work in more controlled situations with advance notification and even follow-up with the same patients if the surgeons can return on a regular basis. When possible, local surgeons can be included allowing us to teach them new techniques.

We are concentrating at this time on working with established groups that send surgeons on regular, scheduled missions. Several of our members already have connections with organizations willing to work with our members. These include AICPE Onlus (Italy), Interplast-Germany (Germany), and CHEIRA (Switzerland). We are also exploring opportunities through Operation Smile and *Médecins Sans Frontières* (Doctors Without Borders). Finally, we are working on obtaining registration of ISAPS as an approved health organization with the United Nations and the World Health Organization. This initiative fulfills the two main goals of ISAPS, education and patient safety.

Dr. Adam Hamawy (United States) has agreed to chair this new initiative to revitalize our Humanitarian Committee. ISAPS members interested in serving in 1-2 week humanitarian missions should contact Dr. Hamawy at [drhamawy@gmail.com](mailto:drhamawy@gmail.com) When responding, please include copies of your medical license and Board certification, a list of languages you speak fluently, and the first page of your passport. These documents are required by all organizations placing surgeons in missions abroad. If you have any contacts within any of the organizations mentioned above or have your own established missions on which you would be willing to include qualified ISAPS members, please let us know.

## WE APPLAUD ALL ISAPS MEMBERS WHO PARTICIPATE IN HUMANITARIAN MISSIONS

We are expanding our efforts to match interested members with existing missions. If you are interested in joining a surgical mission, please contact Dr. Adam Hamawy at [drhamawy@gmail.com](mailto:drhamawy@gmail.com)

Kindly provide copies of your medical license and Board certification, a list of languages you speak fluently, and the first page of your passport. We will begin to coordinate between organizations who are sending surgical missions and ISAPS members.

# ISAPS VISITING PROFESSOR PROGRAM AT UNIVERSITY OF SOUTHERN CALIFORNIA, LOS ANGELES, USA



**NAZIM CERKES, MD**  
Turkey  
ISAPS 1st Vice President  
President, Rhinoplasty Society of Europe

A Visiting Professor Program (VPP) was held at the University of Southern California in Los Angeles on 5-7 March 2018. I spent three days at the Keck School of Medicine, Division of Plastic Surgery, hosted by Dr. Grant Stevens, Director of the USC Fellowship Program, and Dr. Luis Humberto Macias, USC Aesthetic Program Director.



Figure 1 - Dr. Cerkes, center, with Dr. Grant Stevens to his right and Dr. Luis Humberto Macias on the far right with Residents and Fellows during the ISAPS Visiting Professor visit.

The topic was rhinoplasty and I shared my experience and knowledge in this field with the Residents and Fellows of the Keck School of Medicine's Division of Plastic Surgery. On the first day, a three hour "Special Visiting Professor Lecture" on rhinoplasty included surgical videos to demonstrate current techniques. After the lecture, we discussed problem cases with the residents and consultants.

On the second day, I performed a cadaver dissection in the anatomy lab and demonstrated rhinoplasty techniques step by step. The cadaver dissection was videotaped and shown on a large screen. During the dissection, several questions were raised by the participants which allowed for a lively interactive discussion.

In the morning of the third day, I attended surgeries in Marina Medical's outpatient surgery center and commented on the cases. In the afternoon, I gave the "City Wide Keynote Lecture" on rhinoplasty.

The excellent hospitality by the hosts, particularly Drs. Stevens and Macias, included outstanding dinners at the end of each day.

More than thirty participants attended the VPP including Residents and consultant surgeons. Feedback from the participants was positive and the satisfaction was high. This VPP has shown once more that this special ISAPS program is useful in aesthetic education and an important activity to spread the mission of ISAPS - Aesthetic Education Worldwide®.

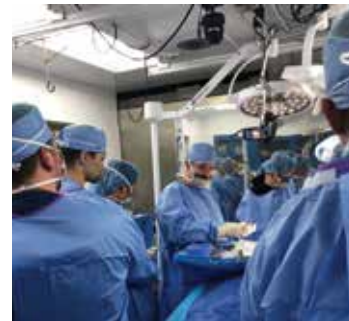

Figure 2 - Dr. Cerkes in the Anatomy Lab.



## Members, do you know that your website access has changed?

Your new website Members Area access Username is now your email. Your password remains your ISAPS Member ID number. Not sure which email to use? Send us an email to confirm. [Membership@ISAPS.org](mailto:Membership@ISAPS.org)

# MESSAGE FROM THE CHAIR OF NATIONAL SECRETARIES



## PETER SCOTT, MD

South Africa  
ISAPS National Secretary of South Africa

Since my last newsletter report, Catherine Foss, Gianluca Campiglio and I have been busy with many National Secretary elections. Of the twenty-eight completed, nine are re-elections of National Secretaries into their second term and twenty are new National Secretaries. Latvia is a new country to have their own National Secretary and we welcome them to our family. We still have three elections outstanding including: Colombia, Azerbaijan, and South Africa ANS. We will conclude all of these by mid-year to allow the office to concentrate on ISAPS Miami 2018.

We completed a very successful ISAPS Official Course in Cape Town, South Africa with twelve international faculty under the direction of our Education Council Chair, Vakis Kontoes. This was our most successful meeting to date with 160 delegates present and full house attendance even into the late afternoon sessions. Alison Thornberry, from the ISAPS office, was present to sign up new members and to sort out membership issues and was able to recruit a number of the younger plastic surgeons to join our society.

Following on from the meeting, a number of the faculty joined me in a very pleasant three-day safari in the Thornybush Game Reserve where we were treated to visits by the Big Five animals, bush breakfasts, dinners in the bush and consolidating the international friendships that make ISAPS one of the most successful societies.

Twenty National Secretaries attended an informal lunch meeting on Saturday, 28 April in New York during the ASAPS conference. Our President, Renato Saltz, EC Chair, Vakis Kontoes, Treasurer, Kai Schlaudraff and Executive Director, Catherine Foss presented updates and we had a great informal discussion.

Our big meeting of course will be the 24th Congress of ISAPS that begins on 31 October in Miami Beach, Florida and we encourage as many of you as possible to attend the National Secretaries Meeting on Tuesday, 30 October. We will be electing a new National Secretaries Chair and Assistant Chair and for those of you who are prepared to increase your involvement in this wonderful organisation, I would encourage you to add your name to the ballot when we look for nominations.

Our new and re-elected National Secretaries and Assistant National Secretaries are:

Bahrain	Rajesh GAWAI, MD - <i>re-elected</i>
Belarus	Dmitry BATIUKOV, MD, PhD
Belgium - NS	Pascal CASTUS, MD
Belgium - ANS	Peter MYNY, MD
Chinese Taipei	Chien-Tzung CHEN, MD - <i>re-elected</i>
Costa Rica	Juan Ramón POVEDA XATRUICH, MD
Denmark	Andreas PRINTZLAU, MD - <i>re-elected</i>
Estonia	Katrin KRUUNVALD, MD
France - NS	Michel ROUIF, MD
France - ANS	Armand AZENCOT, MD
Germany	Magnus NOAH, MD, PhD
Greece	Apostolos MANDREKAS, MD, PhD
Iran	Babak NIKOUMARAM, MD
Italy	Adriana POZZI, MD
Japan - NS	Kotaro YOSHIMURA, MD
Japan - ANS	Hideaki SATO, MD
Latvia	Peteris LAUCIS, MD
New Zealand	Murray J. BEAGLEY, MD - <i>re-elected</i>
Peru	Augusto L. ARRIOLA, MD
Philippines	Rene C. VALERIO, MD - <i>re-elected</i>
Poland	Janusz SIREK, MD, PhD - <i>re-elected</i>
Qatar	Habib B. Saied AL-BASTI, MD - <i>re-elected</i>
South Africa	Ewa SIOLO, MD
Switzerland	Pierre QUINODOZ, MD
Thailand	Kamol WATTANAKRAI, MD, FACS - <i>re-elected</i>
Tunisia	Mourad ZINELABIDINE, MD
Ukraine	Oleg TKACH, MD, PhD
UAE	Luiz TOLEDO, MD - <i>re-elected</i>
USA - ANS	James FERNAU, MD

I look forward to seeing you in Miami Beach in October. In the meantime, if you have any questions, please contact me at [peters@cinet.co.za](mailto:peters@cinet.co.za)



# JOURNAL UPDATE: MESSAGE FROM THE EDITOR OF *Aesthetic Plastic Surgery*



**BAHMAN GUYURON, MD**

United States  
Editor-in-Chief

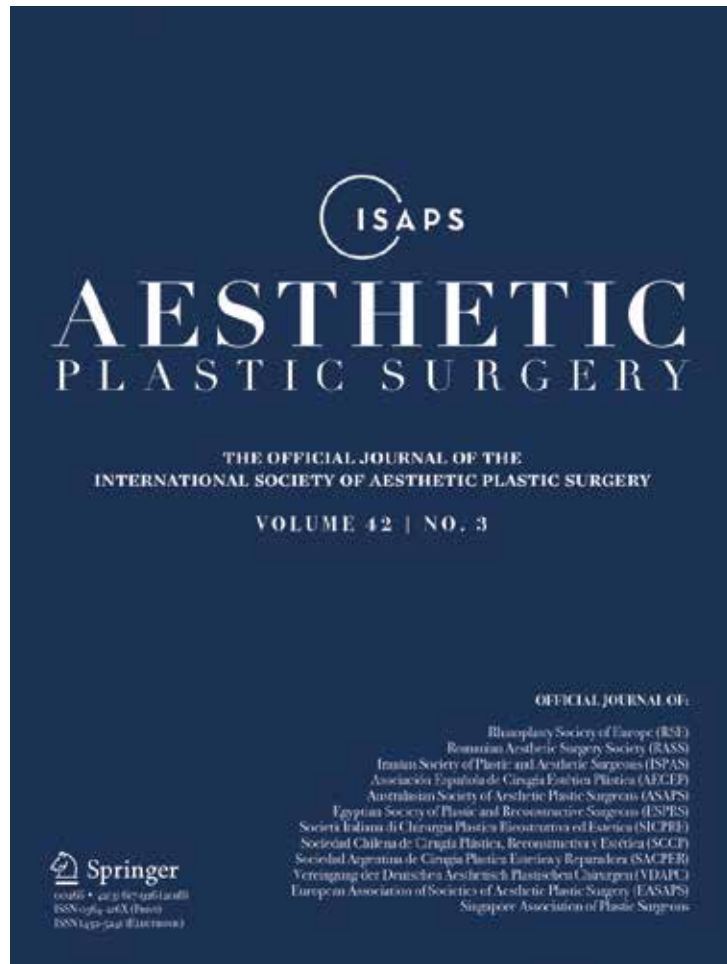We have recently received the statistics report from the publisher related to our team function. I am very pleased with our progress and would like to share some of the improved bench marks that are pertinent, especially to those of you who submit articles to be published in the journal.

The number of submissions has increased by 20 percent. More importantly, the quality of submissions has improved notably, thus the rate of acceptance is higher. Part of the reason for the increase in the acceptance rate is related to the extra efforts by our reviewers. Rather than rejecting an article that has meaningful information, but needs a great deal of work, we, collectively, work with the author as much as needed to make the article worthy of publication, as I have mentioned before. Of course, rejection is an easier course. However, the Editorial Board is keenly aware of the complexity of writing an article and does not want to make a hasty decision or choose the easiest course.

I am also glad to report that the average time from submission to first decision has been reduced from 32 to 15 days, the average turnaround time for peer review is down to 6 days, and the average time from submission to acceptance has been reduced from 90 to 47 days. More importantly, the main mission of the Journal has been restored, which is publication of aesthetic articles or articles that have strong aesthetic connotations.

Our steady progress is primarily due to the hard work of the Editorial Board and many of you who have been reviewing the articles and turning them around as fast as feasible. I am deeply grateful to all of you who have participated in our advancement.

One of the most exciting and new activities is awarding the best article. You will be receiving a list of five articles that have been published during 2016 and 2017 and are nominated for the award. You will be asked to vote for one of these five articles based on the importance to your practice. The results will be announced during the ISAPS Congress in Miami Beach. We will also have the best Resident Free Paper that will be awarded during the Congress.



**We invite you to submit a paper to our journal.**

For information go to:

<https://www.isaps.org/medical-professionals/isaps-journal/>

# HOW TO HANDLE A MEDIA INTERVIEW LIKE A PRO



**JULIE GUEST**

United States  
ISAPS Chief Marketing Officer

An essential skill for all aesthetic plastic surgeons wanting to grow their practice is being able to handle a media interview like a professional. Media interviews can be friendly, neutral or even hostile, and sometimes it's impossible to tell what kind of reporter you've been speaking to until you see the final article. Use these tips to navigate this process with ease!

## BEFORE THE INTERVIEW

1. Think about what the key message is that you'd like to convey. Never, EVER do interviews by simply answering a reporter's questions. If you do, you're missing a fantastic opportunity. Take a cue from politicians, and always have your own agenda determined before you speak to a reporter.
2. Do your homework. A search on both the reporter and the publication he or she is writing for will help you see what kinds of articles have been published in the past, and get an idea of how the reporter approaches his or her work.
3. Write down a list of questions that you anticipate you'll be asked, and prepare some mental notes about the answers you want to give. Sometimes reporters will even send you their questions in advance if you request it, but not always.
4. Think about what resources and references you can provide the reporter with, that can advance your position and expert status (e.g. the International Study on Cosmetic Surgery that ISAPS facilitates each year).

## DURING THE INTERVIEW

Be concise. Don't ramble. Remember that reporters have to work with "sound bites" – not long-winded explanations – so stay away from too many details. Give the most important information, then illustrate with some background. Talk in lay terms, and use medical or technical jargon as little as possible.

Keep in mind that sometimes even forming a question you want to ask can be difficult, without a prior level of understanding, so be patient, and think of your job in the interview as helping the reporter to understand. You can always ask for clarification if a question is unclear. And if you believe a reporter's information is mistaken or imprecise, do not hesitate to straighten it out.

*Be confident. Remember, you are the expert!*

Here are a few more helpful tips during an interview:

- Illustrate your points with examples, stories and anecdotes (of course, always maintaining patient privacy).
- Speak in complete sentences, not partial thoughts. The questions often aren't included in the final article or show, so your responses need to stand on their own.

- If you lose your train of thought, just take a breath. Mentally go over your main points, and then continue on track.
- If you're giving your opinion, make sure you say so. If you're referencing fact, say where you got your information.
- If you can't (or choose not to) answer a question, offer an explanation. For example, "I haven't seen the study you are referring to."
- Don't be afraid of silence. Some reporters can use silence to make you feel uncomfortable, and get you to talk or say things you may not want to say. Stay quiet between questions. It's not your job to keep things moving along.
- Avoid saying anything "off the record." Though an ethical, professional journalist will honor this, you don't want to take that for granted. Always assume that what you're saying is going to be "on the record."
- Make your final comment clear and concise, re-emphasizing your main points and key message.

## AFTER THE INTERVIEW

Summarize the information, main points and your key message, and email this to the reporter. Help put the issue into perspective (i.e., a short history of the issue, how many people it involves, what the trends in the future might be). Also, if you feel that you could have answered a certain question better, this is a great opportunity to re-state, and if you've remembered something that was left out, you can add it now. All of this lets reporters know that you are more than just an interview subject, you are a true resource, and it helps keep you at the top of the list for future interviews.

Finally, ask the reporter if he or she can send you a copy of the article or media clip that you will be featured in. Make sure you to add that you are available for any fact-checking, additional quotes or follow-up they might need!

# MULTI-CENTER, DOUBLE-BLIND CLINICAL STUDY VALIDATES DEFENAGE® AS A BEST-IN-CLASS ANTI-AGING SOLUTION, NATURALLY TURNING BACK THE CLOCK

DEFENAGE®  
skincare

Press Release

## Breakthrough Peptide Reverses Signs of Global Skin Aging in Six Weeks

Carlsbad, CA – April 3, 2018 – Progenitor Biologics®, LLC, the manufacturer and distributor of the cutting-edge anti-aging skin care products, **DefenAge®** Skincare, is proud to announce the results of a new comprehensive clinical study of the line's breakthrough ingredient **Age-Repair Defensins®**. The **defensin**-based three-step system "globally improves the visual appearance of aging skin without irritation, dryness, or inflammation," concludes the peer-review article published by the **Journal of Drugs in Dermatology** (JDD). Target-specific **Age-Repair Defensins** represents the latest generation of anti-aging technology and is the **FIRST** of a kind.

"The **defensin** skin care regimen resulted in statistically significant improvements in ALL five parameters in patients simultaneously including decreased visible fine and coarse wrinkles, pore size and visible pigmentation. Study participants also demonstrated improvement in skin's oiliness, evenness, hydration and a number of other crucial skin's qualities" shares the study's principal investigator and correspondence author, Amy Forman Taub, MD. "**DefenAge** results in profound improvements in the visible health and beauty of the skin that are readily apparent to even the untrained eye."

"The results showed that the **defensin**-containing trio of products offer most of the advantages of time-honored retinols as well as newer but widely used growth-factor containing cosmeceuticals, without irritation or inflammation, sun-sensitivity, or concerns about neoplasia of the treated skin," adds the study's co-investigator, Vivian Bucay, MD. "The observed clinical results put **DefenAge** Skincare into the best-in-class category without doubt, this is a landmark product."

The earlier-published pre-clinical research shows that **defensins** activate dormant preserve of "fresh" cells in the body, LGR6-positive stem cells. "After activation, LGR6-positive stem cells physically migrate into the basal layer of the skin and create a new epidermis, and eventually, new, younger-acting skin," explains the study's co-investigator, Gregory Keller, MD. "The **defensin**-based anti-aging technology is an authentic paradigm shift that I see only once per decade."

"**DefenAge** made an initial soft launch in the summer of 2015," comments Progenitor Biologics' CEO, Nikolay Turovets, PhD. "Today, more than 300 US-based aesthetic physicians and medi-spas offer **DefenAge**. Since the launch, **DefenAge's** annual growth exceeded 100 percent three years in a row, having sales in 2017 that exceeded \$2.4M. Now having such solid clinical proof of the product's performance, we will continue our expansion in the aesthetic market and deliver the best technologies to consumers."

### Study Details

The study was conducted by Amy Forman Taub, MD, Vivian Bucay, MD, Gregory Keller, MD, Jay Williams, PhD, and Darius Mehregan, MD. A participant- and investigator -blinded, placebo-controlled, multi-center trial was performed in outpatient settings on forty-four female subjects, 41-71 years old, skin types I-V. The evaluation was performed at baseline, 6 and 12 weeks. The **DefenAge** 3-step system (trade name: Clinical Power Trio) includes: 2-Minute Reveal Masque, 24/7 Barrier Balance Cream and 8-in-1 BioSerum.

### FULL-TEXT ARTICLE:

**Multi-center, double-blind, vehicle-controlled clinical trial of an alpha and beta defensin-containing anti-aging skin care regimen with clinical, histopathologic, immunohistochemical, photographic, and ultrasound evaluation.**

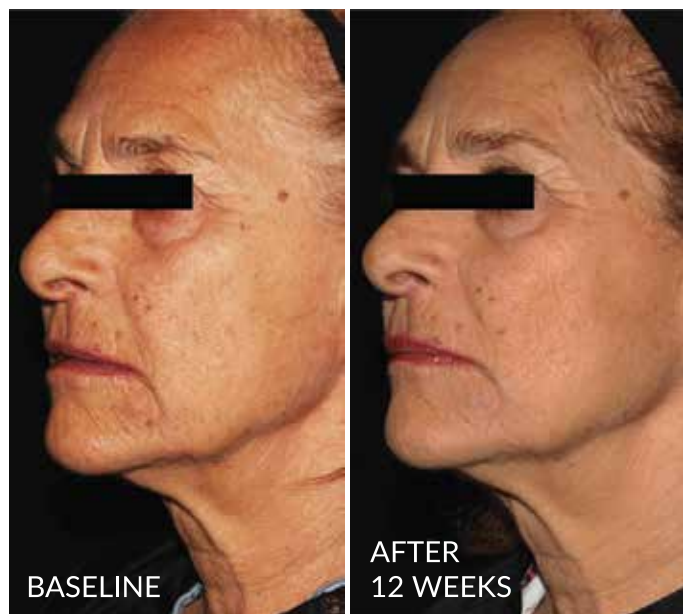Taub A, Bucay V, Keller G, Williams J, and Mehregan D.

*J Drugs Dermatol.* 2018;17(4):426-441.

<http://jddonline.com/articles/dermatology/S1545961618P0426X>



UNRESTRICTED ACCESS



# GLOBAL PERSPECTIVES: OTOPLASTY

Our Global Perspectives series in this issue focuses on Otoplasty. Readers may find it interesting to know that a pioneer of ear reconstruction, Dr. Radford C. Tanzer, lived and worked in Hanover, New Hampshire, which is also the home of ISAPS.

In 1956, an infant born with no outer ear was presented to Dr. Tanzer. After many months of devising a piecemeal approach to the reconstruction of the ear, he successfully completed the surgery in 1957. Fifty years later, I met this child at a small conference held here in Hanover as a memorial to Dr. Tanzer. The child had grown to a man with two perfectly normal ears.

Several of our authors pay tribute to Dr. Tanzer in the articles that follow. The Tanzer classification of ear deformities continues to be used around the world to this day.

Catherine Foss

*ISAPS News* Managing Editor



# EARFOLD: A NEW, FAST, MINIMALLY INVASIVE OTOPLASTY METHOD



**IVAR VAN HEIJNINGEN, MD**  
 Belgium  
 Chair, ISAPS Membership Committee  
 President, EASAPS

Prominent ears are more prevalent than most of us realize. Approximately 5.6% of the adult population has prominent ears, almost half (45%) of these are bothered by their appearance and 35% are motivated to treat their condition. Now if we look at our ISAPS statistics we see only 252,718 ear surgery procedures in 2016!

Where are all these patients then? Most likely most of them are afraid of:

- Duration of the procedure 1-1.5 hours
- Admittance in day clinic
- General anesthesia
- Post-op recovery period including head bandages
- Complications

If we look at all the current procedures, we see 14.7 – 29 % overall complications in cartilage scoring methods, 27.8 – 58 % complications in suture only techniques and 8.8 – 38 % complications in combined techniques. So their fear of hematoma, infection, skin necrosis, suture extrusion, keloid scars, recurrence or re-operations is warranted.

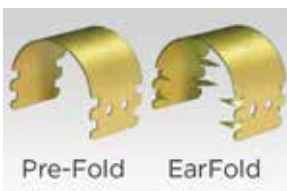This inspired Norbert Kang to develop a new device which proved to have less complications than the classic techniques even in a pilot study published in 2016 in *Aesthetic Surgery Journal*: “Treatment of Prominent Ears with an Implantable Clip System.” I was given the opportunity to start using these devices in Belgium. After theoretical and practical training on pigs’ ears by the developer of the device, I started using the “Earfold” device in 2016.

## WHAT IS EARFOLD?

The device is a clip made of super elastic, fatigue-resistant nickel titanium alloy that functions as a memory metal. It is 0.15 mm thick, weighs 0.068 gram and is gold plated to make it less visible in the subcutaneous plane.

The system consists of two types of clips:

1. The pre-fold positioner that can be used to try out the clip during consultation that accurately mimics the result given by the procedure;
2. The actual implant clip with teeth. A device is used to introduce the flattened clips. The clips are positioned on the helix and produce an antihelical fold.



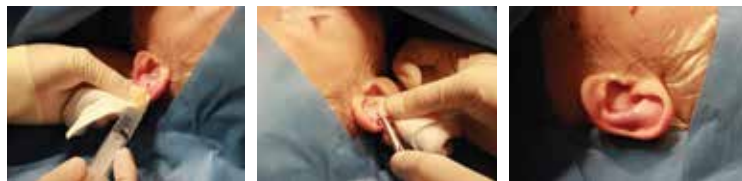## INDICATIONS

Since there is only one clip size, proper positioning is key. It is by no means a procedure that is possible for all prominent ears, nor does it always give the best possible result. The best results are obtained in patients with an absent antihelical fold and flexible cartilage. The pre-fold gives the opportunity to visualize the result before the actual procedure and if this result is not satisfactory to the patient it is best not to proceed and rather offer an otoplasty option. As was mentioned, not all potential otoplasty patients present themselves for correction and it seems

that with this method we address a different subset of patients who are not interested in the conventional techniques. They have different expectations and we as surgeons must be willing to accept that the results are not always what we would like.

## PROCEDURE

The actual procedure, once mastered, is straightforward. After placing the pre-fold, the precise position of the clip is marked on the ear. Pre-operative antibiotics are given. Local anesthesia. Incision a little lateral near the helix edge. Sub-perichondral dissection. Introducing the clip. Positioning and releasing. One suture and steri-strip. The entire procedure can be done in less than 10 minutes. The crucial bit is the positioning and releasing of the clip; it must be flush with the cartilage in the right angle in the exactly correct position to minimize visibility and to create the right effect.



## POST-OPERATIVE

In the post-operative period, it is recommended to refrain from sports and avoid contact with the ear with a telephone. As in all procedures, possible complications are hematoma, swelling, infection and visible scar. Specific to an implant, it can be malpositioned and extrusion is possible. Sensitivity in and around the ear is possible.

## RESULTS



## CONCLUSION

Treatment with the earfold technique is a quick procedure with reduced post-operative complications and faster recovery than the regular surgical corrections. It does not replace current techniques but is an interesting addition to our armamentarium. It might help us tap into a new patient population that has not presented itself yet.

# OTOPLASTY: BRAZIL



**AUGUSTO SETTE CÂMARA VALENTE, MD**  
Brazil

## INTRODUCTION

There are more than two hundred otoplasty techniques described and more than eight hundred related articles in Pubmed. This means that not one technique, by itself, has solved the problem completely. Suture placement and cartilage incision techniques are the two main approaches for correcting prominent ears, represented by modified Mustardé and Converse techniques that are considered best practices today.

## HISTORY

The first publication about aesthetic otoplasty was by Ely in 1881 who removed posterior skin, fixed the Conch region in the mastoid bone and removed a strip of cartilage to break spring memory. Luckett noticed in 1910 that protruding ears were caused mainly by a lack of the Antihelix fold. Several ideas that included incision were created in various positions and directions in the cartilage. After the Gibson and Davis article published in 1958, which demonstrated the natural tendency of the cartilage to curl in the opposite direction of the weakened side, many techniques were published based in the weakening of the cartilage memory, using abrasion, rasp, partial incision, laser, and everything creative that could be imagined to weaken the spring cartilage memory. This weakening of the spring memory works reasonably well in thin cartilage, but when the cartilage is thick and stiff, even if non-absorbable sutures are used, it is sometimes insufficient to overcome the strength of the cartilage. Recurrence rates are high, and the marks of the tactics used to weaken the spring memory of the cartilage sometimes become visible (Fig. 1).

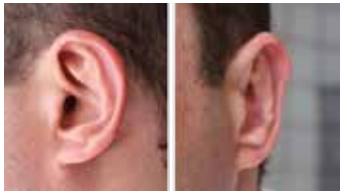

Figure 1 - Ear operated by Converse technique. We can see the distortion and correction of the antihelix.

## TECHNIQUE

In my view, otoplasty does not mean just bringing the ear closer to the skull. All structures should be present naturally without visible marks that make the ear look artificial. McDowell published a list of goals to be achieved in an otoplasty in 1968. Resection or incision in the conchal cartilage must be done in the latter case because it could decrease the patient's auditory acuity.

In a normal ear, there is an angle of ninety degrees between the posterior border of the Antihelix and the scaphoid fossa that should be created in surgery and as a counterpart to the absence of angles or folds that alter the continuity of the cartilage, which begins in the conchal region and goes toward the anterior border of the Antihelix that folds until it encounters the scaphoid fossa at an angle of ninety degrees (Fig. 2). This is important to maintain the structure with a natural design without seeming to have been folded.

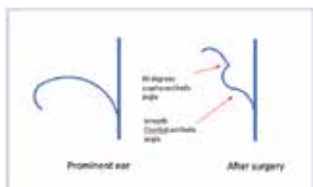


Figure 2 - Pre and Post-op natural angles of auricular pavilion (axial cut)

My technique, published in ASJ in 2010, combines the techniques of John Marquis Converse (US) which completely incises the later border of the



Figure 3 - Direction of the spring beam (arrows) and incision in the cartilage from the triangular fossa down to the tail of the Helix.

Antihelix (Fig. 3) and John Clark Mustardé (Scotland), and maintains the natural fold of the region between the conch and the Antihelix just folding it. In this way, we are able to completely break the spring memory of the cartilage and now we can use this incredible force, in our favor, facilitating the folding of the Antihelix and shaping of the created form with absorbable sutures. The Helix completely disconnected from the scaphoid fossa/Antihelix is completely released to be repositioned with posterior skin resection of the ear pavilion in a drawing like a dumbbell: two ellipses one superior and lower one, with the narrow bridge in the middle third of

the ear. This incision differs from the traditional ellipse design because usually it overcorrects the middle third laterally giving it an artificial appearance.

In ears where prominences are partial (only of the middle and upper third) the incision of the posterior border of the Antihelix stops exactly where the defect ends (Fig. 4). This is a modification created after the publication of 2010, also added an alignment point on the upper border of the Antihelix near the triangle fossa (Fig. 5). This suture was created to avoid recurrence of the upper pole that occurred because it fixes the helix in the Antihelix.



Figure 4 - Partial incision for prominent ear of superior and middle third.

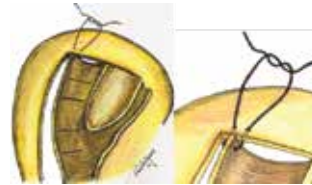
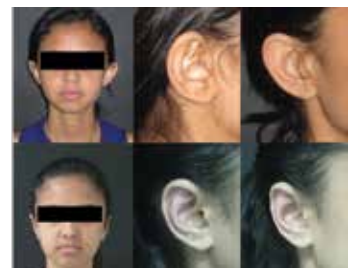
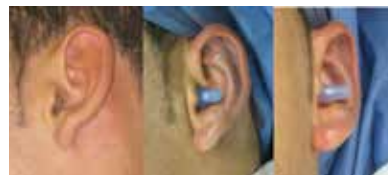
Figure 5 - Alignment point of suture.

The greatest care we must take in this technique is in relation to the postoperative dressing since if it is too tight it can cause epidermolysis and/or necrosis of the undermining skin. The dressing should be soft and not tight.

I have 152 consecutive patients operated by this technique bilaterally, 3.3% of recurrent upper pole, mainly at the beginning of this series and no recurrence after starting the alignment point. The results reach the goals recommended by McDowell, with structures naturally reshaped without the stigma of an operated ear, regardless of the thickness of the cartilage if thin or thick (Fig. 6 and 7).



Figures 6 and 7 - Pre and immediate post-op otoplasty using Valente's technique.

# OTOPLASTY: DEVELOPING A SURGICAL PLAN DEPENDING ON ANATOMIC IRREGULARITY



**RUHONG ZHANG, MD**  
China

Otoplasty is an operation performed to correct mild or moderate auricular deformities, mainly including the prominent ear, the constricted ear, cryptotia, and Stahl's ear. One characteristic of these deformities lies in that there is no obvious absence of auricular cartilage, and thus no need for costal cartilage as a supplement. According to our observations in the past decade or so, each of the above deformities has two or more anatomic irregularities. For the purpose of getting the most satisfactory result, we suggest that a comprehensive preoperative assessment be conducted, and that individualized surgical plans be prepared for different anatomic irregularities.

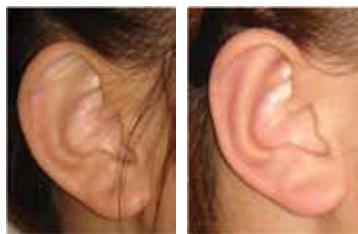## OTOPLASTY FOR PROMINENT EAR

The main causes of the prominent ear are as follows:

1. conchal hypertrophy or excess (upper pole, lower pole, or both);
2. inadequate formation of the antihelical fold (the root, superior crus, inferior crus, or all);
3. a conchoscaphal angle greater than 90 degrees in severe cases; and
4. a combination of conchal hypertrophy and an underdeveloped antihelical fold. Furthermore, lobular protrusion is another cause that is ignored easily.

The correction of prominent ear includes three aspects:

1. Creation of the antihelical fold. Many techniques have been reported to correct the antihelical fold; however, there are two major schools of thought. The first is that a cartilage incision is required - the cartilage-cutting technique. The second is the cartilage-sparing technique which relies on horizontal mattress sutures. The risk of the former is creating visible contour irregularities and sharp edges, and the latter is potential recurrence and suture complications. Of course, there are also combinations of these two techniques.
2. Correction of the conchal defect. Conchal mastoid sutures can be used to correct the conchal excess or prominence of the superior two thirds of the ear. This maneuver brings the concha closer to the scalp and thus reduces the protrusion. This particular technique has the advantage of a thick cartilaginous flap that can be more permanently and precisely anchored to the periosteum while decreasing the tendency to obstruct the external auditory canal. In addition, excisional techniques can be used to reduce conchal hypertrophy. This technique separates the cartilage where the concha meets the tail of the helix and removes an adequate portion along the conchal rim through a posterior approach.
3. Lobule positioning. The posterior skin and subcutaneous tissue of the lobule may be excised in a V, heart, or elliptical pattern and reapproximated for size reduction.



Prominent pre      Prominent post

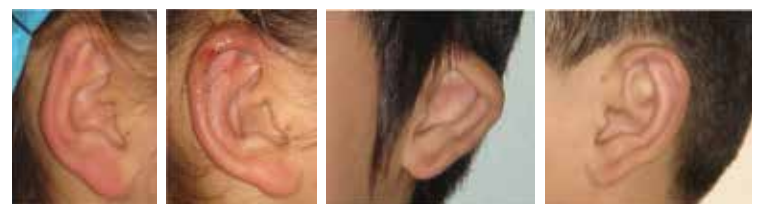## OTOPLASTY FOR CONSTRICTED EAR

This is a deformity of the superior third of the auricle in which the helical rim appears tightened as by a purse-string, pulling the broad helix over the scapha like a hood. The anatomic features of the constricted ear deformity include the following three aspects:

1. The superior helical cartilage is usually acutely folded on itself. In mild cases, the helix merely folds on itself; in severe cases, the upper auricular cartilage sags.
2. The ear may be tilted forward, similar to a protruding ear, and the entire structure may be low set.
3. The auricle is smaller than in a normal ear, and height may be decreased.

Surgeons can use the *Tanzer classification of the constricted ear* to assess the severity of the ear deformity. Surgically, Types I and II are defined as mild and moderate deformities. Type III is considered severe and requires reconstruction of a new ear with the addition of rib cartilage grafts.

1. Type I: Involvement of the helix only. It is easy to release the slightly folded helical rim to achieve favorable results, because there is sufficient skin relative to the slightly folded cartilage.
2. Type IIa: Involvement of the helix and scapha, and no supplemental skin needed at the margin of the auricle. Management of the auricular cartilage with or without supplementation involves adjusting the anterior helix, filleting the deformed helix and scapha, and reconstructing the upper pole of the ear. No supplemental skin is needed to manage the soft tissue.
3. Type IIb: Involvement of the helix and scapha and supplemental skin needed at the margin of the auricle. To supplement and expand the auricular cartilage, conchal cartilage grafts from the ipsilateral or contralateral side are often used as supporting cartilage. The harvested costal cartilage is used to construct the auricular defect in severe cases.



IIA Pre      IIA Post      IIB Pre      IIB post



# EARFOLD: EXPERIENCE AND RESULTS AFTER TWO YEARS OF APPLICATION



**ISABEL VALINOS, MD**  
Germany



**ERNST MAGNUS NOAH, MD, PHD**  
Germany  
ISAPS National Secretary for Germany

EarFold™ is an innovative method of correcting prominent ears in which the result can be demonstrated before the operation. Unlike traditional otoplasty, the Earfold™ method makes it possible to create the missing fold in the ear without removing skin and without stitches thanks to a small implant made of nitinol (an elastic nickel-titanium alloy (see Fig. 1). Earfold™ is generally suitable for all patients with little to no antihelical fold and offers many patients a perfect alternative to traditional corrective ear surgery.

Earfold™ has been CE-certified since April 2015 and is approved in Europe for adults and children ages 7 and up. Current results in 403 patients (1,200 Earfold™ implants) can be seen in the study recently published in PRS Global Open (January 2018). It was invented by Norbert Kang, a plastic surgeon at the Royal Free Hospital London. We in Kassel received first-hand training and are some of the first users in Germany. We are also a training center.



Fig. 1 - The Earfold system

## INITIAL EXPERIENCE

We have been using the Earfold™ method since October 2016 and are currently overseeing 50 implants in 21 patients. Our experience to date has been positive:

- Prefold simulation can provide a highly accurate representation of the expected result before the operation.
- The intervention is simple to conduct under local anesthesia.
- The result is visible immediately after the operation. Patients can go right home after the operation without any special bandages. There is no need to wear a headband.
- Side-effects are minor: Swelling and slight bruising generally disappear after 7 days.
- Slight visibility of the implants after the swelling subsides and does not bother most patients.
- In the event of problems with the skin or the area around the implant, the latter can be easily removed under local anesthesia.

Suitable candidates	Unsuitable candidates
<ul style="list-style-type: none"> <li>• Patients with underdeveloped or missing antihelical fold (see Figs. 2+3)</li> <li>• Soft cartilage</li> <li>• Patients for whom traditional otoplasty is not an option, e.g. due to recovery time, wearing a headband or the length of the operation</li> </ul>	<ul style="list-style-type: none"> <li>• Patients with concha hyperplasia (also possible in combination with concha resection, if necessary)</li> <li>• Ear/cartilage anomalies (consideration with Prefold simulation)</li> <li>• Patients with nickel allergy</li> </ul>



Fig. 2 - Patient before the operation (top) and 4 weeks after the intervention (bottom).



Fig. 3 - Patient before the operation (top), with Prefold simulation (center) and after the operation (bottom).

## OPERATION PROCEDURE AND TIMESPAN

- Implant position determined once again with patient in front of a mirror (Prefold simulation) and drawn on (3 minutes)
- Sterile washing and covering (2 minutes)
- Single-shot antibiotic, such as cefazolin (infection prevention) - optional
- Local anesthesia 1-2ml Xylonest 1% with added adrenaline (hydrodissection) (1 minute)
- Skin incision 4-5mm
- Subperichondral pocket preparation (5 minutes each)
- Implant placed via applicator (15 seconds), see Fig. 4
- Skin closure (Vicryl rapid 6/0) (1 minute)
- Great auricular nerve block anesthesia 5ml ropivacaine (postop. pain prophylaxis) - optional (1 minute)

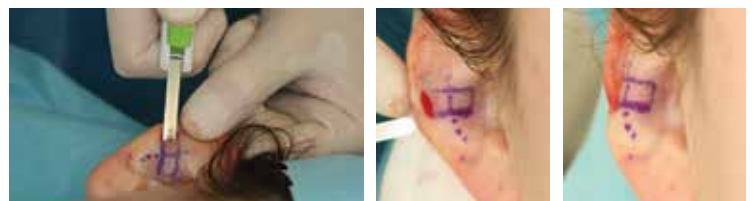

Fig. 4 - Implant placement

Continued on page 34



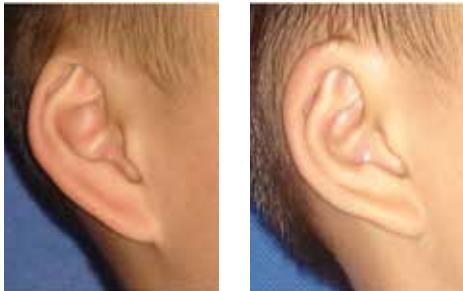ZHANG CONTINUED

**OTOPLASTY FOR CRYPTOTIA**

The anatomic structures of cryptotia most often present as one of the following two deformities:

1. Embedded upper auricle: the superior aspect of the ear is hidden beneath the temporal scalp;
2. Adhesion of the upper auricular cartilage: this malformation is recognized when the surgeon manually pulls out the upper pole of the ear.

Treatment of cryptotia includes releasing the cartilage from under the skin, correcting the cartilage adhesion, and covering the released ear cartilage with either local skin flaps or skin grafts.



Cryptotia Pre

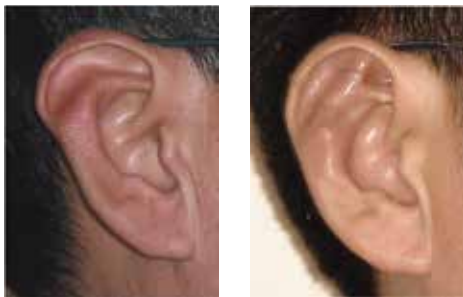Cryptotia post

**OTOPLASTY FOR STAHL'S EAR**

This deformity mainly manifests as an excess third crus that is frequently accompanied by the angulation deformity of the helix and a broadening of the scaphoid.

Corrections include:

1. Elimination of the third crus;
2. Creation of a natural helix;
3. Creation of the superior crus;
4. Reduction in the abnormal widened scaphoid.



Cryptotia Pre

Cryptotia post

*Dr. Zhang is Vice Chairman of the Department of Plastic and Reconstructive Surgery at the Shanghai 9th People's Hospital and Professor of Plastic and Reconstructive Surgery at the School of Medicine, Shanghai JiaoTong University. He is also a member of the Executive Committee of the International Society of Auricular Reconstruction and General Secretary of the Chinese Society of Plastic Surgeons. Email: [zhangruhong@163.com](mailto:zhangruhong@163.com); [zrhm@msn.com](mailto:zrhm@msn.com)*

NOAH/VILANOS CONTINUED

Complications	Revisions
• Swelling, bruising (Fig. 5)	Generally self-limiting; cooling if necessary
• Temporary pain	Ibuprofen, LA with ropivacaine if necessary
• Long-term pain	Removal of implant
• Infections, impaired wound healing	Administer antibiotics, removal of implant if necessary
• Hypertrophic scars (Fig. 6)	Cortisone infiltration, removal if necessary
• Skin erosion, implant breakout	Removal of implant
• Palpability/visibility	usual explain to patient before operation!

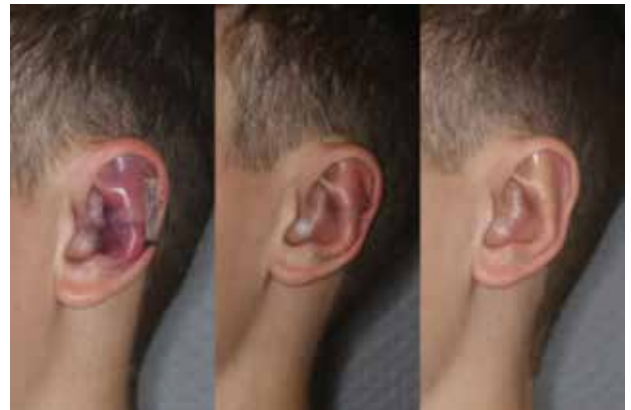

Fig. 5 - Bruising after 1 day (left), after 1 week (centre), result after 4 weeks (right)

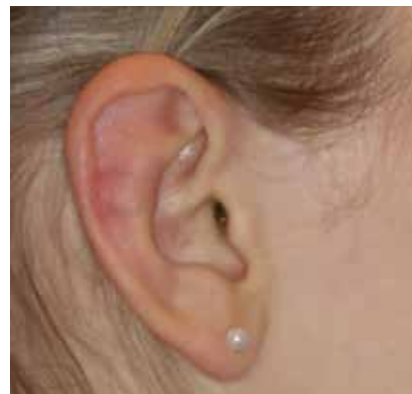

Fig. 6 - Hypertrophic scars

**RECOMMENDATION**

Providing a good indication and successful simulation, Earfold™ is an excellent minimally invasive alternative to traditional otoplasty. Earfold™ addresses a heretofore unmet need in cosmetic otoplasty, especially with patients for whom conventional methods are not an option for the reasons mentioned above.

If applied carefully, the side-effects are minor and above all, positive and permanent results with great patient satisfaction can be achieved.

*The authors have no financial or other interest in any company or product mentioned in this article.*

# THE PROMINENT EAR: CORRECTING SPECIFIC PROBLEM AREAS TO ACHIEVE NATURAL RESULTS



**ADRIANA POZZI, MD**

Italy  
ISAPS National Secretary for Italy

During the third month of gestation, the auricle increases protrusion and at the end of the sixth month is almost completely formed. The curvature of the helix, the fold and the crura of the antihelix are already visible. Anything that interferes with this process can produce prominent ears. This deformity causes potential psychological side effects that may occur in four or five-year-old patients, and correction may change a child's self-image and personality.

The most common deformity is the unfolded antihelix which widens the conchoscaphal angle, sometimes more than 150 degrees which, in severe forms, flattens the superior crus, body of the antihelix and inferior crus. In some cases, the fold of the helix may be absent. Protrusion of the concha may be isolated or in conjunction with the other deformities described above.

Achieving symmetry in prominent ears is one of most important goals, and it may be more difficult to obtain in unilateral deformity.

On a front view, the helix must be visible behind the body of the antihelix. Laterally the helix rim should be between 17 and 20 mm from the scalp. The surgeon's artistic eye is an adequate measuring tool before surgery - placing the helix into a new position with gentle pressure until it appears in "right" position.

In otoplasty, the best way to proceed is to correct specific problem areas of each individual ear rather than performing a routine repeated operation.

An absent or weak antihelix requires creation of the fold. Our approach has changed over the years. At the beginning, we used to score the medial cartilage surface using Dingman oto-abrader rasps. Now we do it only in exceptional situations, when the cartilage is very strong and not easily pliable. Most of the time, we prefer simple hydrodissection of the anterolateral skin from the cartilage with saline injected through a 30-gauge needle, just before passing each permanent -4/0 Mersilene-Mustardé mattress suture. This works very well in preventing recurrence of the deformity.

After restoring the anti-helical fold, if the middle third is too prominent, one must recess the concha by either cartilage excision or suture fixation (with concha mastoid sutures, as described by Furnas). Finally, if the lobule protrudes, one single suture, attached to the tail of the helix, is placed at a lower level of the concha, to stabilize and bring in the lobule.

Usually, in adult patients, we perform the correction of protruding ears under local anesthesia with sedation. For children, general anesthesia is preferred.

The best symmetrical results are achieved after careful pre-operative evaluation, and accurate positioning of the sutures during the operation. In the final result, the repaired ear convolutions should appear smooth for a non-operated look.



Figure 1A - A 9 year old patient with prominent ears, characterized by wide conchae and lack of anti helical fold.



Figure 1B - Correction by Mustardé mattress sutures and elliptical excision of excess concha.

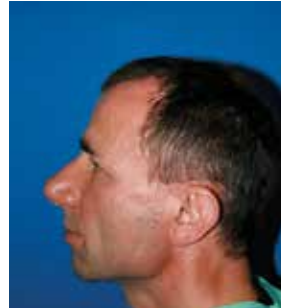

Figure 2A - A 42-year old patient with prominent ears, characterized by lack of anti helical fold.

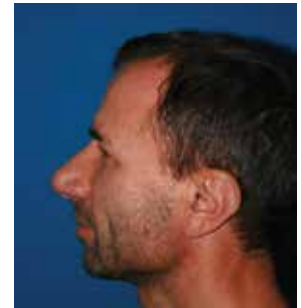

Figure 2B - The anti helical fold has been restored without scoring the cartilage by hydrodissection and Mustardé mattress sutures. A smoother and natural antihelix has been achieved.

# REDUCTION OTOPLASTY: AN UNCOMMON AESTHETIC REQUEST



**GIANLUCA CAMPIGLIO, MD, PHD**  
Italy  
ISAPS Secretary

## INTRODUCTION

Ear reduction, also known as reduction otoplasty, is the least popular among the aesthetic operations of the external ear. In these patients, it is the correction of excessive size of the pinna (*macrotia*) and not the protrusion of the ear from the mastoid and/or the absence of the anti-helix fold as in the standard otoplasty. Anthropometric studies by Farkas have established a standard of normal measurements of ears for North American Caucasians. By the age of 19 for male and 18 for female, when ear growth is completed, mean measurements are 62.4 (length) by 35.4 (width) mm in males and 58.8 (length) by 33.5 (width) mm in females. Ethnic variations show that the average ear size of blacks tends to be smaller whereas ear measurements among Asians are in between.

Historically, a full thickness wedge resection, preferably at the widest part of the auricle, was the simplest method to treat macrotia, but very often this leads to a deformation of the ear requiring additional excisions from the scapha and the concha. Several modifications of this method have been subsequently described in the literature, but all of them left extended and visible scars on the lateral surface. Positioning of a crescent shape excision in the helical groove made these scars less evident and improved the aesthetic results. In recent years, very few articles have been published on this type of surgery mostly based on resections of small parts of the enlarged ear and advancement of the helix toward the lobe.

## TECHNIQUE

The procedure is performed under local anesthesia plus sedation and can be done in conjunction with standard otoplasty or as an isolated procedure aimed to reduce the size of the ear only. The first incision is made in the helical groove starting in the triangular fossa and arching towards a V shaped cut at the junction of the mid and lower third of the helical rim (Fig.1). The excess of scapha (skin and cartilage) is resected (Fig.2-3) and the skin behind the remaining scapha and concha dissected thus raising the helical rim as a large condro-cutaneous flap. At this point the excess of concha is excised (Fig.4) and the remaining defect closed (Fig.5). Finally the condro-cutaneous flap is advanced inferiorly and the excess of rim and post-auricular skin is trimmed. All the wounds are sutured with fast reabsorbable stitches (Fig.6).

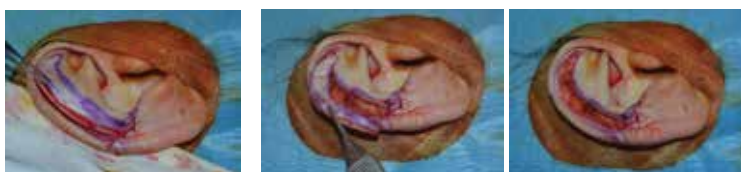
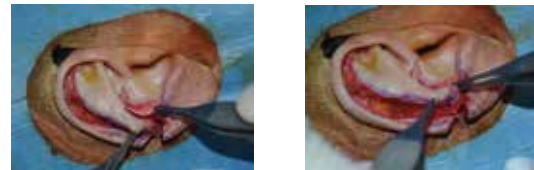
Figure 1 - Operation is started with an incision in the helical groove. Figures 2 - 3 - The excess of skin and cartilage from the scapha is removed.

## COMMENTS

This technique is a classic example of how a procedure, initially proposed for reconstructive cases in which large parts of the auricle have been amputated following traumas or tumors, can be used when a reduction of the size of the ears is sought for aesthetic purposes (Fig.7). In all the eight patients that I treated bilaterally, the unavoidable scars are inconspicuous and the contour of the ear is natural and regular (Fig.8). In only one case a notching defect has occurred where the stumps of the helical pedicles are brought together and this required a minor revision after three months.



Figures 4 - 5 - The excess of skin and cartilage from the concha is also removed

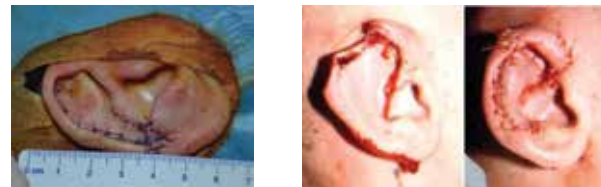

Figure 6 - The wounds are sutured with fast resorbable stitches.skin and cartilage from the scapha is removed.

Figure 7 - Post-traumatic subtotal amputation of the auricle and its immediate reconstruction using the same technique.skin and cartilage from the scapha is removed.

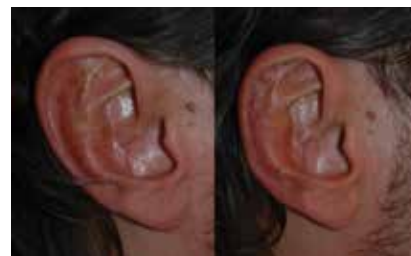

Figure 8 - Pre and post-operative result of a young male requiring aesthetic reduction of the size of his external ears.

## REFERENCES

1. Farkas L. Anthropometry of normal and abnormal ears. Clin Plast Surg 5:401; 1978
2. Wegener H. Correction of protruding ears in combination with reduction surgery of hyperplastic auricle. Aesth Plast Surg; 5:57; 1981
3. Argamaso. Ear reduction with or without setback otoplasty. Plast Reconstr Surg, 83:967; 1989



# OTOPLASTY



## PETER SCOTT, MD

South Africa

ISAPS National Secretary of South Africa

### INTRODUCTION

Otoplasty is a procedure that hovers on the cusp between reconstruction and aesthetic surgery and is often not covered in congresses and symposia. Fortunately, this will feature at the ISAPS Congress in Miami in Miami in October-November this year. Medical insurance in most cases will no longer cover this procedure and the patients and parents are far more fussy now than they used to be. They expect perfect symmetry post-operatively whereas the adage “these are not twins but sisters/brothers” applies. No one sees the details of both ears simultaneously. We have looked for a logical approach to the prominent ear and combined the techniques of Furnas, Davis, Mustardé and Dingman. The anatomy is well known to all of us and the important structures to consider here are the concha, anti-helix, superior crus, inferior crus and lobule.

Four aspects of the ear are considered and these are the concha mastoid angle, the depth of the concha, the anti-helical fold and the tail of the helix. Each is treated on its merits. We no longer create a new anti-helical fold, but rather take the existing fold and modify it. Ideally, the helical rim should be 17mm from the mastoid bone and the ideal age for surgery is between six and seven years. We find that after the age of ten, the cartilage thickens and the redo rate increases while under the age of five, the patients battle to co-operate with the dressings. As with rhinoplasty surgery, beware the obsessive males in their 20's (SIMON).

### TECHNIQUE

A conservative skin ellipse is excised with a slightly more dumbbell pattern over the lobule and the top of the pattern curved posteriorly to avoid a pleat in that area (fig. a). The ear is de-gloved posteriorly up to the helical rim and down to the mastoid. If concha mastoid sutures are proposed the dissection is continued into the post auricular area and these sutures are positioned using 4/0 PDS but avoiding distortion of the external auditory meatus (fig.b).

The conchal ellipse is marked out accurately using a needle and ink to avoid taking away too much or going to close to the anti-helical fold (fig.c). This is carefully excised, avoiding buttonholing anteriorly and then using a Littler scissors with the tip curved posteriorly, the anterior aspect of the ear is de-gloved.

At this point, Dingman Otoplasters are used to score the anti-helical fold on the anterior surface scorings on the bias to avoid formation of grooves or sharp edges (fig.d). The conchal ellipse is closed with 4/0 PDS interrupted sutures. Attention is then turned

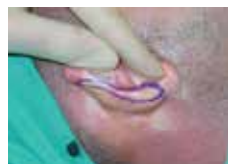

Figure a - Skin Excision.

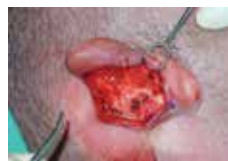

Figure b - Concho mastoid sutures

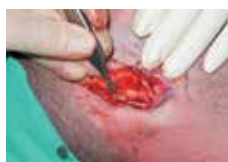

Figure c - Conchal ellipse excision

to the tail of the helix. There are various methods to attend to this and the most reliable I have found is a direct excision of the double cartilage to allow the ear lobe to relax into the correct position (fig.e).

There may be some skin memory, but this will correct with time. Mustardé sutures are then used doing the superior most one first to get the curve of the superior crus accurate and about 3 or 4 sutures are used (fig.f). This is the most important part of the operation and if the curve is not correct or if there is buckling it should be redone (fig.g). Often, a needle and ink technique will help with the accurate placement of these sutures. There is debate as to the correct type of suture and I tend to use a monofilament 4/0 clear nylon on a reverse cutting needle. I have used PDS previously and I am concerned that a relapse might occur. Occasionally, these sutures will extrude up to a year post surgery and as long as the patient is pre-warned, it does not become a major issue.

Skin closure is with 4/0 rapid Vicryl and my dressing involves acriflavine soaked cotton wool to mould into the anterior portion of the ear and paraffin gauze with some antibiotic ointment posteriorly (fig.h). I then use Reston foam with a cut-out for the ear with some gauze padding to avoid pressure necrosis of the anti-helical fold (fig.i).

My childproof dressing, which also applies to adults, is two crepe bandages, 4 inch, one vertical and one horizontally around the head secured with Elastoplast with a small amount of the Elastoplast securing the dressing to the forehead (fig.j). This is kept in position for ten days. A similar head bandage is used to avoid the ears folding over while the patient is sleeping for a further two weeks at night. Sport and exercise is avoided for four weeks and contact sport for six weeks. Initially the ears look a little bit over corrected, but over a six-month period should settle into a pleasing position.

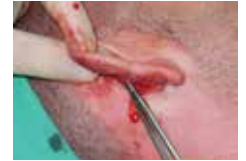

Figure d - Dingman otoplasty

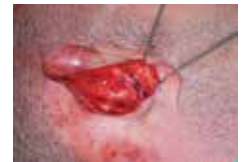

Figure e - Trim tail of helix

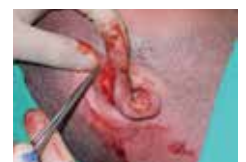

Figure f - Mustarde suture

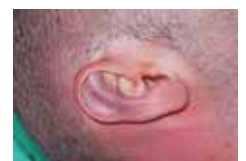

Figure g - Correction completed

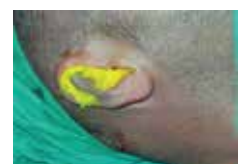

Figure h - Acriflavine cottonwool dressing

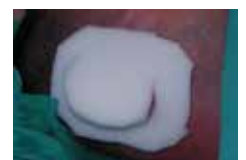

Figure i - Reston Foam dressing

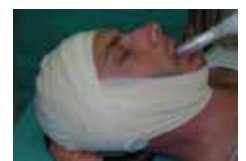

Figure j - Completed head bandage



## SCOTT CONTINUED

### COMPLICATIONS

We have seen haematoma from early trauma, necrosis of the skin over the anti-helical fold which is then treated conservatively with antibiotic ointment dressings. This may well be from the pressure of the dressing or from the patient scratching at the ear and in children we recommend that they keep the finger nails very short.

Keloid scars, especially in the darker skins we encounter in Africa, are a serious problem and as a result we avoid any anterior incisions. Should this occur we will put them onto a keloid management program which involves injections of triamcinolone, silicone dressings or paste, re-excision and as a last resort re-excision and radiotherapy. Stitch extrusion is a possibility and chondritis is more of a problem with the permanent braided sutures.

### LONG TERM PROBLEMS

The anti-helical fold is too sharp and this is due to over-zealous otobrasion. There are those who do not do any scoring of the anterior cartilage. Cartilage overlap is more common in the Chong-Chet procedures.

Buckling of the anti-helical rim is more common in the very soft ears or young patients. This may be anticipated at the time of surgery and the conchal ellipse excision cartilage used as a batten or brace for this area.

Telephone ear is a result of skin shortage. This comes from surgeons who try to do the correction by removing too much skin and the answer to this would be to release the skin and put a full thickness graft in to correct this and advancing post auricular skin to the post auricular groove.

Prominent lobule is a result of not attending to the tail of helix and this can be managed with a small correction.

Relapse occurs in about 5% of patients under the age of ten and over the age of twenty can go up to 10-15%. I usually try to make the patient wait up to six months and then re-do the Mustardé sutures.

There are a number of specific congenital problems such as microtia, lop ear, and scaphoid ear, but the treatment of these is outside the scope of this article.

### CONCLUSION

These are very grateful patients and it is not necessary to wait for them to be teased at school before offering them surgery, but to go on clinical grounds. The four-step approach discussed is a fairly bomb-proof technique that senior surgeons and residents alike will be able to utilise and get consistent, reliable results (fig.k) and (fig.l).



Figure k - Pre-Op



Figure l - Post-Op, one year

## GLOBAL PERSPECTIVES: FUTURE THEMES

**September 2018: Management of the Neck**  
**Deadline: July 15**

**December 2018: Regenerative Medicine**  
**Deadline: October 15**

To contribute an article of 500-750 words, please forward it to ISAPS@isaps.org with the subject line: ISAPS NL Series. This should be a non-referenced opinion piece of several paragraphs giving your observations and perspectives on the topic. What do you do in your practice? What unique approaches do you use? What do you see your colleagues doing in your country or region? Photos are welcome, but must be high resolution JPG files attached, not embedded in your article. Photo captions are always helpful.

## GUESS WHO?



Answer: Alex Verpaele and Ivar van Heijningen at a Resident Mafia costume party in the 1990s.

# GLOBAL PERSPECTIVE SERIES: OTOPLASTY



**MARISA MANZANO SURROCA, MD**  
Spain

A few years ago, a new technique emerged to either complement or treat cases for prominent ears: Earfold™. After one year using it, we have started to understand who the best candidates are to undergo the procedure. It may seem quite easy, but it has a long non-negligible learning curve.

The system is designed in a way where the patient can see the final result prior to the surgery. This is one of the advantages as well as a fast way to insert the device with a reduced postoperative period. But it has some drawbacks.

The folding angle of the device is fixed which is why the treatment is not personalized. The other disadvantage is that it is not a good solution if the cartilage in the scapha is weak because it produces an indentation. We still do not have enough experience to ensure suitability for the asymptomatic permanence of this device over time.

The two main complications we have found are visibility and pain. This has to be explained very carefully because in both cases the treatment may be extraction and conversion to a classic otoplasty with stitches and/or scoring. Malposition has to be considered a technical error and can be repositioned.

We use to give prophylactic antibiotics since it is a foreign body. Of all the patients we have treated, we have 89% good or very good results without any setback, but in cases that developed a complication, we have realized over time that the best solution is to remove the device and transform the procedure to otoplasty.

Another detail is that 75% are male. This can be explained by two main reasons: men usually wear short hair making the ears more visible and since they do not have to be off work it is very attractive. We have not used more than two Earfolds™ per ear and it might be a long-term mistake because we add more risk.




Figure 1 - Immediate post-op result. This patient has one Earfold on the left side to correct asymmetry.

Infection has been another complication that has always ended in a removal or the Earfold™. Since usually the other ear has not had any problem, we wait at least 3 or 4 months to reinsert again, but it has to be done in a very careful way because the cartilage is weaker after the process and you can make a perforation.

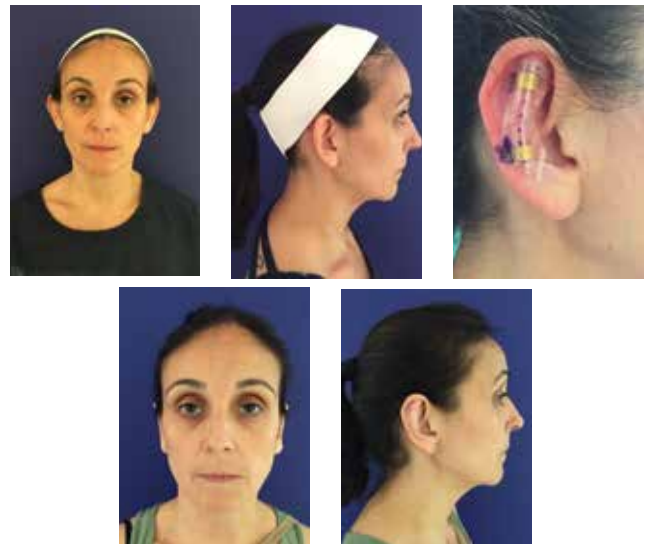

Figure 2 - Six-month post-op result. This patient has two Earfolds in each antehelix.

At this time, we have not used it in patients under 18 years of age, but it can be done in pediatric ages for correct indication even under local anesthesia in prepared children.

Overall, this is a technique to be taken into account in specific cases and we cannot reject that it can be complementary to any otoplasty technique. In the end, the number of first visits to the consultation has increased to request information and already in this first visit with the pre-fold we can advise on its indication, and if not indicated, then otoplasty is the technique to be advised in order to correct the wide angle of concha-mastoid or too big ears or whatever problem they have that cannot be addressed with Earfold™.

The author has no financial or other interest in any company or product mentioned in this article.

# EAR RECONSTRUCTION: SEARCHING FOR THE NATURAL CURVE



**AKIRA YAMADA, MD, PHD**  
United States

The auricle is virtually never the focus when we talk about facial “beauty” or “attractiveness.” Why?

One of the principal reasons is that the auricle is located away from the center of the face — at the side of the head, sitting on the temporal bone, behind the face mask. We only pay attention to the auricle when its appearance is not natural, when it appears too prominent, too high, too low, or has a pointed helix.

The natural auricle is a miracle to me — composed of a delicate elastic cartilage framework that is wrapped by a well-perfused and thin skin envelope. In nature, the spiral curve creates beautiful architecture such as the shell of the nautilus, and the architecture of the auricle is, in fact, similar to the nautilus, composed of multiple-layers of spirals. However, surgeons remain unable to reproduce perfect auricular architecture to date, and the question is: how can we make the best surgical auricle we can, one that comes close to the shape and integrity of the natural ear?

The autogenous rib cartilage framework for auricular reconstruction was pioneered by Radford Tanzer in the 1950s, and it has been refined by many surgeons, including, importantly, Burt Brent and Satoru Nagata. I was fascinated by Brent’s results when the first edition of *Plastic Surgery* (McCarthy) was published in 1990, but at that time I could not understand precisely *why* I was fascinated by his auricles. I could not imagine that twenty-seven years later, I would be honored to become the author of an ear chapter in the fourth edition of *Plastic Surgery* (Neligan). In order to determine why Brent’s ear is so fascinating, I began to study the curves of the human face with my research partner Toshinobu Harada (a professor of industrial design at Wakayama University in Japan) in 2009, and together we discovered the answer: the helix-lobule curve created by Brent is almost always Type A and the Type A helix-lobule curve is one of the three major types of helix-lobule curves we discovered in nature (Fig. 1). Not only that; it is the smoothest type of curve in nature.

Back in 1996, I had the opportunity to observe Satoru Nagata’s surgery, and I was deeply impressed by the beauty but difficulty of his surgical techniques. In order to become his disciple, I quit my job as an assistant professor at a rural university in Japan immediately after I saw Nagata at work. Then, I spent the next three and a half years with him before I felt I was ready to perform his techniques by myself.

After we discovered that there are three major types of helix-lobule curves in nature, Professor Harada and I analyzed Nagata’s framework curve and found

that both Brent and Nagata use the same Type A helix-lobule curve (Fig.1). Interestingly, neither Brent nor Nagata are aware of this similarity. Like any other part of the human body, the auricle has specific balance and harmony. Its width is 0.5-0.55 of its vertical height, posteriorly inclined 15-20 degrees. The auricle is located one-ear-length behind the lateral canthus and it is twenty millimeters behind the bit of lateral facial hair

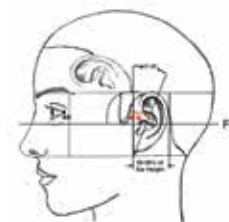


Figure 2

that is sometimes called the side burn. The entrance of acoustic meatus is not located in the midline but is located below the midline (Fig. 2). I have come to believe, in addition to these classical teachings, that creating specific curves is the critical component of ear reconstruction in making the construct beautiful.

**In nature, the spiral curve creates beautiful architecture such as the shell of the nautilus, and the architecture of the auricle is, in fact, similar to the nautilus, composed of multiple-layers of spirals.**

In 2009, I was invited by Dr. Mitch Stotland to give the keynote lecture at the Third Biennial Radford C. Tanzer, MD Plastic Surgery Symposium at Dartmouth Medical School in Hanover, New Hampshire, along with Burt Brent, Theodore Bogosian, and Scott Spear. I was also honored to be the first outside surgeon to perform auricular reconstruction at the Dartmouth-Hitchcock Medical Center which is considered the world’s Mecca of ear reconstruction. This meeting was small, but it was also the best intimate scientific meeting I have ever attended. Dr. Tanzer’s very first microtia patient was invited to the meeting, and I observed personally that his autogenous rib cartilage reconstruction was well-maintained fifty years after it was surgically created.

I have followed a patient of my own for over ten years now. Although that is a far shorter length of time, her ear shape is very well maintained (Fig. 3). She is able to wear her hair in any style — something that is highly important for almost all female auricular reconstruction patients. She does not hide the reconstructed auricle with her hair. Although neither I nor any of my colleagues can create perfect replicas yet, I nonetheless still strongly believe that to date autogenous rib-cartilage reconstruction remains the gold standard treatment for microtia.

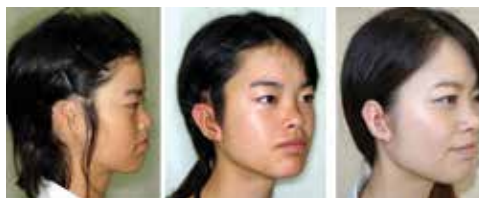

Figure 3

Guest author, Dr. Akira Yamada, is Professor of Surgery in the Department of Plastic Surgery at Northwestern University’s Feinberg School of Medicine and Ann & Robert H. Lurie Children’s Hospital of Chicago. He has written and lectured extensively on ear reconstruction.



# CURRENT TRENDS IN OTOPLASTY



**FRANK AGULLO, MD, FACS**  
United States

Hundreds of techniques for correction of ear deformities have been described. Hence, no single procedure is superior to others. The most common deformity I encounter is the protruding ear. This deformity is usually caused by the absence of the antihelical fold or excessive conchal bowl.

Ideally, the timing of the repair should be between 3 and 5 years, before starting school. Unfortunately, my experience with insurance coverage for correction of protruding ears has been poor. Even though I cite that protruding ears can be cause for difficulty with using protective gear like helmets and the obvious ridicule and self-esteem issues early in life, I have had less than 2% of cases covered. This would probably explain why most of my patients are adults who can finally take care of the deformity financially. The story of being victims of bullying, self-esteem deficiency, and self-consciousness about the problem repeat in almost all of these patients.

In my practice, non-surgical correction of ear malformations has been very effective if started within the first two weeks of birth. I use the EarWell system (Becon Medical, Tucson, AZ) to splint and mold the ear (Figure 1). The system consists of a

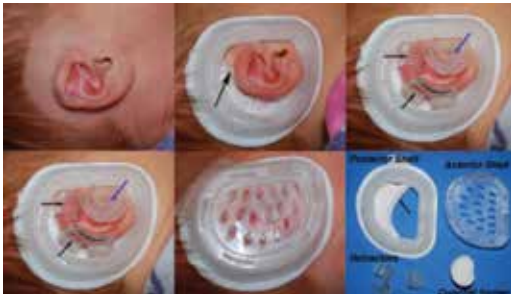

Figure 1 - EarWell system and stepwise application of the molds and components.

posterior shell with a posterior conformer, helical rim retractors, a conchal former, and an anterior shell. The posterior conformer is adhered to the retroauricular sulcus and aligned guiding the antihelical fold to create the superior limb of the triangular fossa. Retractors are used to shape the helical rim while providing an anterior force on the scapha. The conchal former is placed in the conchal cavity to exert downward force at the conchal-mastoid angle. Compressible foam may be added to obtain the appropriate height of the conchal former. Lastly, the anterior shell is affixed to the posterior cradle securing all components of the device while applying an anterior force. The device is changed every two weeks. Treatment lasts from 4 to 8 weeks. I have been very satisfied with the results (Figure 2).

For all other patients, surgical intervention is indicated. I prefer cartilage-sparing techniques over cartilage-cutting maneuvers such as wedge excisions, scoring, or abrasion, to avoid anterior

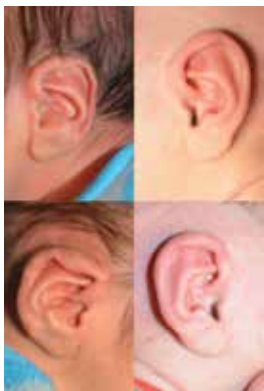

Figure 2 - Before and after photos of a 3-month-old male who underwent the EarWell molding treatment beginning at week 2 from birth for lop and protruding ear deformity. Patient was treated for 6 weeks.

pinna irregularities. I prefer to use permanent sutures, rather than cutting, to create the desired auricular contours. In my opinion, this preserves the cartilage support and minimizes contour irregularities. I use multiple horizontal mattress sutures to recreate the antihelical fold as described by Mustardé and conchal-mastoid mattress sutures to decrease the projection of a deep conchal bowl as described by Furnas.

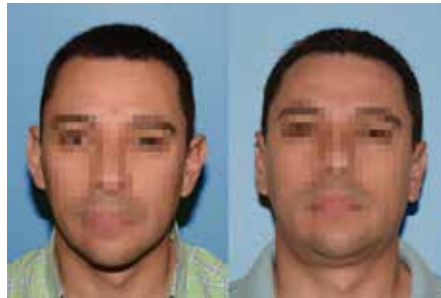

Figure 3 - Before and after photos of 41 year-old male after otoplasty protruding ears one year after.

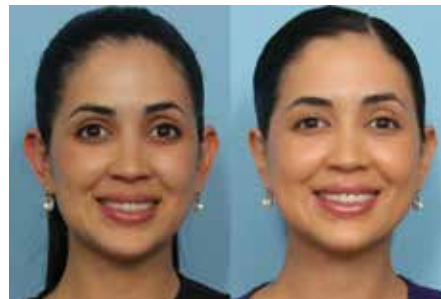

Figure 4 - Before and after photos of 30 year-old female after otoplasty for protruding ears one year after.

These procedures are usually performed under local anesthesia, local anesthesia with oral sedation, or local anesthesia with intravenous sedation depending on the patient's level of anxiety. Satisfaction rate is very high, but I have observed through the years, that most adult patients seeking correction of the protruding ear desire overcorrection. It is very interesting to see the patients at their month follow up showing off their ears as well as hearing stories of how they used to hide them. (Figures 3-4).

*The author has no financial or other interest in any company or product mentioned in this article.*



# GLOBAL PERSPECTIVES: OTOPLASTY



**PATRICIA GUTIERREZ-ONTALVILLA, MD**  
Spain  
ISAPS Assistant National Secretary for Spain



**ENRIQUE SALMERON-GONZALEZ, MD**  
Spain



**EVA LOPEZ BLANCO, MD**  
Spain

I have been doing otoplasty since I finished my residency in 2004. I work in a public hospital as a pediatric plastic surgeon. Prominent ear is the most common deformity of the external ear; its prevalence is estimated at 5%. Despite that this aesthetic deformity causes no physical limitations, it may have a great psychological and social impact.

In my region around Valencia, Spain, otoplasty is included in the portfolio of the national health system, but only for children until they are 15 years old. Although many surgical techniques have been described, none of them has proved to be the best in this field. My preference is using a modified Furnas technique. Other colleagues in my hospital use the Mustardé technique with similar rates of satisfaction and complications. Before surgical correction, some important principles should be kept in mind according to McDowell's goals of otoplasty:

- Emphasis should be placed on the correction of the upper third of the protruded ear.
- When viewing the patient anteriorly, the helix should be visible behind the antihelix.
- The helix should have a smooth and continuous contour, not broken or sharp.
- The postauricular sulcus should not be distorted or markedly decreased in size.
- Each part of the helix should be at an appropriate distance away from the mastoid skin. This is between 10 to 12 mm in the upper third and 16 to 18 mm in the middle third, and 20 to 22 mm in the lower third of the ear.
- At any point between the two ears, the position of the lateral ear border to the head should match within 3 mm of each other.

## MODIFIED FURNAS TECHNIQUE

Our emphasis should be placed on the correction of the upper third of the protruded ear and the excess of concham auris if it occurs. An hourglass shaped incision is made behind the ear, marking an extended skin resection area. Cartilage is exposed through a supraperichondrial plane. When necessary, concham auris cartilage resection and cartilage weakening with a rasp is performed. Cartilage weakening is made from an anterior approach, through a new incision hidden under the helix. If an excess of height of concham auris occurs, I manage it resecting a "spindle" piece of concham auris cartilage. After that, two or three Furnas sutures (conchamauris setback sutures) with 4.0

prolene are applied. No Mustardé sutures are utilized. A simple continuous suture with 4.0-vicryl rapide TM (poliglactin 910) is utilized for wound closure.

After modified Furnas technique, betamethasone 0.5mg/g-soaked gauzes are placed in order to support the newly shaped area and control early postoperative bleeding and swelling. Dry gauzes are placed over the ear and covered with a compressive headband. After the second day, patients are allowed to take the gauzes off and clean their wounds on a daily basis. Headbands are utilized for four weeks (continuously the first two weeks and only at night the second two weeks). Antibiotic is only administered during surgery; no antibiotics are provided after surgery.

All patients are operated under general anaesthesia, the surgery takes between 35 and 50 minutes, and patients are discharged 4 to 6 hours after surgery.

Between 2012 and 2016, we performed 356 paediatric otoplasties. 105 patients underwent a modified Mustardé otoplasty and 83 were operated utilizing the modified Furnas technique. The ages ranged from 6 to 15 (average 9.97). Primary surgery was performed on 168 patients and secondary surgery on 20 patients (eleven patients were operated in our service). There were two cases of local infection and were treated with abscess drainage and oral antibiotics. Retroauricular keloids were managed with intralesional triamcinolone infiltrations and we only required surgical excision in one case.

Neither technique showed better results than the other in terms of complications or success rates and both rates coincide with reports in the literature for other techniques.

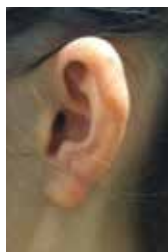

Figure 1 - Pre-Otoplasty

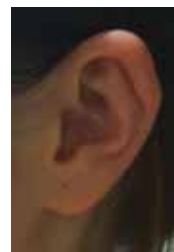

Figure 2 - After Modified Furnas technique

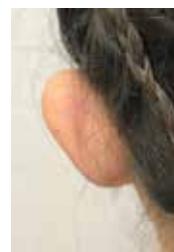

Figure 3 - Pre-Otoplasty Posterior View

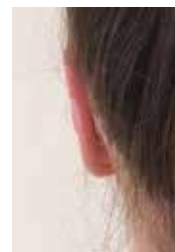

Figure 4 - Post-Otoplasty Posterior View



Fig 5 - Nine years old girl. Post-otoplasty. Posterior view



Fig 6 - Nine years old girl. Pre-otoplasty. Posterior view.



Fig 7 - 22 years old woman. Pre-otoplasty. Posterior view.



Fig 8 - 22 years old woman. Post-otoplasty. Posterior view.

The authors have no financial or other interest in any company or product mentioned in this article.



# THE 24<sup>TH</sup> CONGRESS: THE GREATEST AESTHETIC EDUCATION ON EARTH!

- Registration is already at a record breaking 1300.
- 90% of our exhibit hall is sold.
- Master Classes and Cadaver Courses are selling fast.
- Don't forget to buy tickets for the Beach Party.
- Bring your office staff and family.

**#SeeYouInSouthBeach!**

# SOUTH BEACH VS. MIAMI BEACH, WHAT'S THE DIFFERENCE?

Ok, we think it's time we cleared a few things up!

The response we've already been getting about the 2018 ISAPS Congress in South Beach, Florida, has been wonderful. Plastic surgeons from all over the world are already getting excited to come to South Beach, both for the Congress itself and for the incredible nightlife, food, and beaches.

One of the most common questions we are getting about the Congress is about the location itself. Lots of plastic surgeons are looking online for information about "South Beach" and search engines are giving them lots of information about "Miami Beach" instead. What gives, Google?

Well, it is very easy to explain. South Beach, one of the most popular places to visit in the United States, is a neighborhood of Miami Beach, Florida. So, South Beach technically IS Miami Beach, but only a part of it. Both Miami Beach and South Beach have lots to offer travelers and each is equally deserving of a visit, depending on what you are looking for.

## SOUTH BEACH



South Beach is an experience, to put it mildly. If you are looking for one of the most vibrant spots in North America, you've found it. In parts, it is like a non-stop party of fun and excitement with a nightlife that is world-renowned. We don't know how much club-hopping you will be doing during the Congress, but if you are staying for a few days afterward, it is definitely something that you want to check out.

In South Beach, you are also going to find some of the best cuisine imaginable, along with some of the best seafood in North America. The population of South Beach includes representatives of many Latin countries, so if you want authentic Latin cuisine, your taste buds will be in heaven.

Something that South Beach is famous for is its Art Deco architecture. Colorful buildings and façades line the streets, some of them you might recognize from the famous 1980s TV show *Miami Vice*. There are daily tours to see these buildings, or you could simply take a walk and go on a self-guided tour. Either way, they are a sight that you simply have to see.

## MIAMI BEACH



If you are looking for somewhere a little bit more laid back and relaxed, Miami Beach, just north of South Beach, is where you can find some peace and quiet. The crowd tends to be a little older and the feel of the city is a little slower, an atmosphere that many people with families prefer.

As Miami Beach proper is a little less focused on excitement, you won't find the same emphasis on delicious food and fabulous entertainment that you will in South Beach. That said, it is absolutely worth a visit (It's about a \$20 cab ride away from South Beach and the Congress.)

The big thing that both South Beach and Miami Beach have in common are the incredible beaches. These sandy white beaches stretch for miles, from South Beach straight up north to Miami Beach proper. The feeling of the beaches is actually quite similar to the locations themselves. The beaches of South Beach tend to be a little more active, with beach volleyball and slightly bigger crowds, while the beaches up north are a little smaller and more laid back. It really all depends on what you are looking for in a beach experience.

So, what is the difference between South Beach and Miami Beach? The neighborhood of South Beach, where the Congress is being held, offers a much more exciting, vibrant experience than the rest of Miami Beach. Mind you, that isn't putting Miami Beach down, the entire city is incredible and well worth the time you should put into exploring it.

If you've attended ISAPS Congresses in the past, you know just how popular they are. They offer an incredible experience to the attendees, with access to some of the world's most knowledgeable plastic surgery experts.

Registering today for the Congress and reserving your room at the Loews Miami Beach Hotel will save you a headache when it starts to get a bit closer. This is one of the premiere global aesthetic meetings in the world, and you do not want to miss this chance to make new friends and new contacts and learn from some of the greatest ISAPS plastic surgeons in the world.

To download the Congress registration brochure to view the full program go to <https://isaps.memberclicks.net/assets/docs/ISAPSRegistrationBrochure.pdf>



# LOOKING FOR A MEMORABLE DINING EXPERIENCE IN MIAMI BEACH?

## LOBSTER BAR SEA GRILLE

Location: 404 Washington Avenue, Miami Beach, Florida 33139



A glittering restaurant in the heart of South Beach, Lobster Bar Sea Grille showcases world-class seafood, prime steaks, and unparalleled service in a vibrant, up-scale setting.

Learn more here:

<https://buckheadrestaurants.com/restaurant/lobster-bar-sea-grille-miami-beach/>

## LA CÔTE

Location: 4441 Collins Avenue, Miami Beach, Florida 33140



La Côte at the Fontainebleau Hotel offers sweeping views of the ocean and the expansive pools. The outdoor restaurant features a delicious Mediterranean inspired menu and specialty cocktails.

Learn more here:

<https://fontainebleau.com/dining/la-cote/miami-beach-oceanside-dining>

## LARIOS ON THE BEACH

Location: 820 Ocean Drive, Miami Beach, Florida 33139



Larios on the Beach is an award-winning restaurant in Miami Beach known for its authentic Cuban cuisine, world famous mojitos and stunning views of Ocean Drive. Created by Miami's own musical luminaries, Gloria and Emilio Estefan, the restaurant offers a lively atmosphere on the weekend with a live band.

Learn more here: [lariosonthebeach.com/index.html#aboutus](http://lariosonthebeach.com/index.html#aboutus)

## SANTORINI BY GEORGIOS

Location: 101 Ocean Drive, Miami Beach, Florida 33139



Located on the famed Ocean Drive and inspired by the beautiful island of Santorini Greece, this beachfront restaurant is intimate and elegant, pulsing with the energy and excitement that Miami Beach demands. The menu features the freshest Greek cuisine that Miami Beach has to offer.

Learn more here: <http://www.santorinibygeorgios.com/the-restaurant/>

## CECCONI'S

Location: 4385 Collins Avenue, Miami Beach, Florida 33140



Cecconi's is a modern day classic Italian restaurant serving hand-made pasta, seafood and dishes from Italy using the finest ingredients. The restaurant is located in a beautiful open-air courtyard of the Soho Beach House and offers an elegant and relaxing atmosphere for guests.

Learn more here: [www.cecconismiamibeach.com/#menu](http://www.cecconismiamibeach.com/#menu)

## THE BAZAAR BY JOSE ANDRES SOUTH BEACH

Location: 1701 Collins Avenue, Miami Beach, Florida 33139



The Bazaar by, James Beard Award-winning Chef, José Andrés has a vibrant mix of sophisticated cuisine amongst a playful indoor-outdoor space by Philippe Starck. The menu blends Andrés Spanish heritage and personal ingenuity with influences from the local Latin culinary tradition.

Learn more here:

<https://www.sbe.com/restaurants/locations/thebazaar-southbeach/#about>



# MEMORABLE DINING CONTINUED

## THE LIDO BAYSIDE GRILLE

Location: 40 Island Avenue, Miami Beach, Florida 33139



The Lido Bayside Grill at The Standard Spa, Miami Beach takes its inspiration from the traditional Mediterranean diet and lifestyle. The menu features organic meats and fish, olive oil, fresh herbs, unprocessed foods, grill cooking and biodynamic wines. The restaurant is located on Belle Isle, a quiet island tucked away from the action of South Beach where guests can enjoy their meal set amidst peaceful gardens and a breezy outdoor terrace overlooking the bay.

Learn more here: [www.standardhotels.com/miami/features/bayside-grill](http://www.standardhotels.com/miami/features/bayside-grill)

## MALIBU FARM MIAMI BEACH

Location: 4525 Collins Avenue, Miami Beach, Florida 33139



Malibu Farm at the Nobu Hotel at Eden Roc is a bright and airy, South Florida outpost of Helene Henderson's Californian restaurant and the epitome of laid-back luxury. Directly overlooking the Atlantic Ocean, the restaurant boasts simple farm-to-table dining all day that is fresh, organic and locally sourced.

Learn more here:

<https://www.edenrochotelmiami.com/en/things-to-do/eat-drink/malibu-farm-oceanfront-miami-beach-restaurant>

## HABITAT

Location: 2341 Collins Avenue, Miami Beach, Florida 33139



Habitat offers a menu of New Traditional, International Cuisine and is located at the 1 Hotel South Beach. Chef Jose Mendin fuses masterful Michelin-star techniques with farm-fresh ingredients drawing from Spanish, Latin and Asian traditions for a complete sea to table experience.

Learn more here: <https://www.1hotels.com/south-beach/taste>

## MR CHOW

Location: 2201 Collins Avenue, Miami Beach, Florida 33139



MR CHOW's menu features a combination of old authentic Beijing and original recipes and boasts one of the best prepared Beijing duck in the world. Located directly on the beach at the W Hotel, the restaurant features indoor seating, a spacious outside dining patio and interior bar and lounge. The stunning dining room is centered by a unique 123 foot Gold-leaf and Swarovski crystal chandelier designed by Michael Chow.

Learn more here: <http://www.mrchow.com/restaurant-miami-menu-map>

## JOE'S STONE CRAB

Location: 11 Washington Avenue, Miami Beach, Florida 33139



A Miami Beach family owned staple since 1913, Joe's has grown into the place to go for stone crabs. The restaurant is open only during stone crab season from October through May making this restaurant high on the list of restaurants to see and be seen. Long wait times are expected but if you don't want to wait to be seated in the restaurant there is a take-away café next door where guests can enjoy Joe's favorites without the wait.

Learn more here: <http://www.joesstonecrab.com/>

## A FISH CALLED AVALON

Location: 700 Ocean Drive, Miami Beach, Florida 33139



A Fish Called AVALON is located on Ocean Drive directly overlooking the Atlantic Ocean. The menu features fresh American seafood with tropical influences and embodies the vibrant energy of South Beach with a Latin-Caribbean entertainment duo that plays every evening on the front porch.

Learn more here: <https://www.afishcalledavalon.com/>



# 24TH CONGRESS OF ISAPS EXHIBITORS & SPONSORS

We thank the following companies for their support of our 24th Congress in Miami Beach. Our exhibit hall is 90% sold at the time of publication. For information about exhibiting, contact the Executive Office for a current floor plan and exhibitors and sponsors brochure – [ISAPS@isaps.org](mailto:ISAPS@isaps.org)

- A to Z Surgical – US  
AccuVein, Inc. – US  
Advice Media, LLC – US  
Alastin – US  
**Allergan, PLC – US – KEY SPONSOR, ISAPS CONGRESS**  
American Institute of Aesthetic Medicine (AIAM) – US  
American Silicone – US  
Anthony Products/Gio Pelle – US  
ASAPS – US  
ASPS – US  
ASSI-Accurate Surgical & Scientific Instruments – US  
Aston Baker Cutting Edge – US  
Atlas KPI – US  
Bellaire/Meopen – US  
Biodermis – US  
Black & Black Surgical, Inc. – US  
Blaine Labs, Inc. – US  
Bomed – China  
Bovie Medical – US  
BQ Ergonomics LLC – US  
Brumaba - Germany  
BTL Aesthetics – US  
Candela – US  
Canfield Scientific, Inc. – US  
Clearpoint Medical, Inc. – Canada  
CosmoFrance – US  
Crisalix – Switzerland  
Crystal Clear Digital Marketing – US  
DefenAge Skincare – US  
Dermato Plastica Beauty Co., Ltd. – Chinese Taipei  
Design Veronique – US  
Designs for Vision, Inc. – US  
Doctor's Toy Store, Inc. – US  
Dp Dern LLC – US  
Dr. Miami – US  
DRE Medical – US  
Ecla'dor – France  
Ellis Instruments, Inc. – US  
Elsevier Inc. – US  
Embody – France  
Enova Illumination – US  
Envy Medical – US  
Estheticon s.r.o. – Czech Republic  
FAGA Medical – Brazil  
FotoFinder Systems, Inc. – US  
Galatea Surgical, Inc. – US  
Hanson Medical, Inc. – US  
human med AG – Germany  
Ideal Implant Inc. – US  
Illusio Imaging – US  
Image Skincare – US  
Implantech Associates, Inc. – US  
Incredible Marketing – US  
InMode – Canada  
Interni USA, Inc. – US  
Invotec International – US  
IPSAC – France  
Jac-Cell USA Inc. – US  
JETT – Czech Republic  
Jeunesse Innovations – US  
Laboratoires Arion – France  
Leonisa – US  
LIPOELASTIC a.s. – Czech Republic  
Liposales, Inc. – US  
MAAM Garments (Tex Access MCV s.r.l.) – Romania  
Marena Recovery – US  
Marina Medical Instruments, Inc. – US  
MD Resource – US  
Mentor Worldwide, LLC – US  
**Merz North America, Inc – US – PLATINUM GLOBAL SPONSOR**  
MicroAire Surgical Instruments – US  
Microsurgery Instruments – US  
Millennium Medical Technologies – US  
Miramar Labs, Inc – US  
MirrorMe3D - US  
**Motiva USA LLC – US – GOLD GLOBAL SPONSOR**  
MTF Biologics – US  
Nanjing North Vision Co., Ltd. – China  
Neodyne Biosciences – US  
**NeoGraft – US – BRONZE GLOBAL SPONSOR**  
PMT Corporation – US  
**Polytech Health & Aesthetics – Germany – PLATINUM GLOBAL SPONSOR**  
Quality Medical Publishing Inc. – US  
Red Spot Interactive – US  
Restoration Robotics – US  
Roya.com – US  
Sciton, Inc. – US  
Seattle Software Design – US  
Shippert Medical Technologies Corporation – US  
Sinclair Pharmaceuticals Ltd. – France  
SmartGraft by Vision Medical, Inc. – US  
Sontec Instruments, Inc. – US  
Stille – US  
Studio III Marketing – US  
Suneva Medical – US  
The Hydrafacial Company – US  
Thieme Medical Publishers – US  
Trilogy Laboratories – US  
TubEvac/Godsdcv – US  
Tulip Medical Products – US  
Utah Medical Products, Inc. – US  
Vivell s.a.s. – Colombia  
Viveve – US  
VOE, S.A. – Spain  
Ward Photonics – US  
Wells Johnson Company – US  
Wolters Kluwer – US  
Xelpov Surgical Ltd. (PVT) – Pakistan  
Zalea – US  
Zero Gravity – US  
ZO Skin Health – US



# ARE YOU COMING?



## 24TH CONGRESS

**OCTOBER 31 - NOVEMBER 4, 2018**

**South Beach Miami, Florida, United States**

**#ISAPSMIAMI2018**

# ACCEPTED ABSTRACTS AT THE ISAPS CONGRESS

## ARGENTINA

Hugo Loustau, MD  
*The Owl Technique Combined with the Inferior Pedicle in Mastopexy*

Horacio Mayer, MD, FACS  
*The Suprapubic Dermoadipose Flap for Aesthetic Reshaping of the Postpregnancy Abdomen*

Marcelo Robles, MD  
*Successful Buttock Augmentation with Implants*

Juan Seiler, MD  
*Evolution of the Transconjunctival Lower Eyelid Blepharoplasty*

Richard Huggins, MBBS  
*Bony Aging of the Tear-Trough: High Resolution CT Analysis of 400 Cases From Birth to 100 Years of Age*

Frank Lin, MBBS, FRACS  
*Lymphatic Vessels as a Potential Pathway for Retrograde Spread of Infection Following Peri-Orbital Filler Injections*

Simone Matousek, MBBS (Hons), PhD, FRACS (Plast)  
*An Anatomical Study of the Gluteal Fold and its Relevance in Understanding the Effects of Surgery in the Gluteal Region and Liposuction Danger Zones*

Morris Ritz, MBBS, FRACS  
*Post Op App*

## AUSTRIA

Harald Beck, MD  
*The Lipobodylift*

Georg Huemer, MD, MSc, MBA  
*The Tit-Procedure: Tissue-Implant Technique in Autoaugmentation Mastopexy*

David Lumenta, MD, PhD  
*Role of Antibiotics in Capsular Contracture*

Johannes Matiassek, MD  
*Influence of an Octenidine Based Wound Gel on Postoperative Wound Healing and Scarring After Abdominoplasty*

Thomas Rapp, MD  
*Volumetric Hand Rejuvenation, Anatomical Guidelines for an Optimal Filler Placement*

Raphael Wenny, MD  
*Lipobodycontouring in the Outpatient Setting - Safety First!*

## AZERBAIJAN

Nigar Sultanova, PhD  
*The Application of Microlipografting for Correction of the Secondary Posttraumatic Enophthalmos*

## BAHRAIN

Rajesh Gawai, MCh  
*Penile Enhancement*

## BELGIUM

Marwan Abboud, MD  
*Power-Assisted Liposuction Mammoplasty (Palm): A New Technique for Breast Reduction*

Christine Deconinck, MD  
*French Translation and Linguistic Validation of a New Patient Reported Outcome Instrument: The Body Q. A Description of the Process*

Hiba El Hajj, MD  
*A Novel Approach in Breast Reconstruction: The Flip-Over Fascio-Cutaneous Thoracodorsal Flap Combined with Loops*

Alexis Verpaele, PhD  
*An Evidence-Based Protocol for Lip Lifting*

## BOLIVIA

Maria Teresa Zambrana Rojas, MD  
*Laser Blepharoplasty with 980nm Diode*

## BRAZIL

Fernando Amato, MD  
*Quilting Suture and Suction Drain in Patients Undergoing Surgical Treatment of Gynecomastia*

Jaime Anger, MD  
*The Use of Soft Silicone Solid Implant Molded Intraoperatively for Pectus Excavatum Surgical Repair*

Juan Arbeláez, MD  
*Reduction Mammoplasty and Mastopexy with Posterior-Inferior Flap: Our 23 Years of Experience*

Astrid Ardila Bernal, MD  
*Pilous Density Post Facelift Surgery High-Performance Protocol in Otoplasty*

Rubem Bartz, MD  
*Reverse Abdomen, Technique and Variants*

Miluska Bromley, MD, MSC  
*Progressive Tension Sutures in Abdominoplasty: How Many are Enough?*

Augusto Camara Valente, MD  
*Treatment of Back Rolls: A Novel Technique*

Andre Cervantes, MD  
*Assessment of Preferences and Complications Related to Gluteal Fat Graft Among Brazilian Plastic Surgeons*

André Colaneri, MD  
*New Classification of Labia Minora Hypertrophy and its Correlation with Surgical Techniques*

Erico Consoli, MD  
*Correction of Protruding Ears*

Marco Tulio Cunha, PhD  
*Periareolar Mammoplasty for the Treatment of Massive Gynecomastia with Breast Ptosis*

Alvaro Daher, MD  
*The Central Area of the Face - Post Primary Rhytidoplasty in the Last 5 Years in Ivo Pitanguy Institute*

Marcelo Daher, MD  
*Star Nymphoplasty: A Surgical Technique for Labia Minora Hypertrophy*

Franciele De Freitas, MD  
*Treatment of Eyelid Bags and Dark Circles Using MD Codes Technique*

Domingos De Paola, MD  
*"Round" Mini-Lift - A Simplified Fast Recovery Mini-Macs Lift*

Zulmar De Vasconcellos, PhD  
*Facial Angioedema on Cervical Lifting Patient: A Case Report*

Yhelda Felicio, MD  
*Breaking Paradigms about Breast Reduction - Axillary Approach*

Julio Fernandes, MD  
*Guidelines for a Safer Liposuction: A Multidisciplinary Overview*

André Frisina, MD  
*Analysis of Techniques of Umblicoplasty in Aesthetic Abdominoplasty*

Paulo Godoy, MD  
*Intramuscular Gluteal Augmentation with Implants Associated with Immediate Fat Grafting*

Nelson Letizio, MD  
*Correction of Ectropion in Secondary Blepharoplasties Through the Transconjunctival Approach*

Marcio Littleton, MD  
*Effective Mucosa-Muscularis Autograft: A New Sex Change Technique*

Rodolfo Lobato, MD  
*Conservative and Piezolectric-Assisted Rhinoplasty in a Tessier No. 0 Facial Cleft Bifid Nose: Case Report*

Rafael Lopes, MD  
*Fat Grafting for Correction of Asymmetry in Pectus Excavatum*

Barbara Machado, MD  
*Measuring Skin Improvement with 3D Stereophotogrammetry Imaging-System*

Walter Marrou, MD  
*Anchoring Sutures in Maintaining the Position of the Abdominal Scar, A Randomized Clinical Trial*

Maria Roberta Martins, MD  
*The Use of Micro Fat Graft in the Face and Neck Lift*

Marcel Menezes, MD  
*Evaluation of the Nasolabial Sulcus Improvement After High Density Fillers in the Malar Region. "The Approach of CK1, CK2, CK3 Mdcodes®"*

Antonio Minuzzi, MD  
*Miniabdominoplasty with Umbilical Floating*

Almir Nácul, MD  
*Facial Volumetry - Over 20 Years of Experience with Injectable Fillers*

Alexandre Nunes, MD  
*Closed Lift - The 1.5 cm Temporal Incision to Complete Midface and Brow Lift*

Bianca Maria Ohana, MD  
*Rhinoplasty - The Challenge of Teaching and Being Always Learning - 50 Cases with My Residents*

Osvaldo Pereira, MD  
*Labioplasty with Inner Thigh Anchoring (Suturing) to Obtain a Precision Resection*

Juliano Pereira, MD  
*Trade Marks on Buccal Fat Pad Excision "Bichectomy"*

Guilherme Pintarelli, MD  
*Nano and Microfat Graft Combined to Facelift Surgery*

Pedro Pita, MS  
*Treatment of Nasogenian Fold Which Muscle or Fat Graft*

Marco Regazzo, MD  
*The 20-15-5 (TFF) Technique for Effective and Safe Gluteal Fat Grafting*

Rafael Ribeiro, MD  
*Prevalence of Body Dysmorphic Disorder in Plastic Surgery and Dermatology Patients: A Systematic Review with Meta-Analysis*

Raphael Rocha, MD  
*Results and Complications in Abdominoplasty: 3 Years Retrospective Review*

Franz Rojas, MD  
*Analysis of the Fat After Liposuction and Processed by Different Methods by Flow Cytometry for Fat Grafting*

Marina Rosique, MD, PhD  
*How to Select the Ideal Breast Reshaping Technique After Bariatric Massive Weight Loss?*

Fernanda Scala, MD  
*Long-Term Solutions for Ptotic Breasts Using Autologous Breast Tissue*

David Sena, MD, PhD  
*How to Develop a Productive Content Creation Routine for Digital Medical Marketing*

Ricardo Silveira, MD  
*Photshop as Tool for Evaluate Abdominoplasty Associated with Liposuction in Female Body Contouring*

Joao Sobral Filho, MD  
*Augmentation Breast Mastopexy*

Adriane Tartare, MD  
*Use of Myocutaneous Blepharoplasty Flap for the Treatment of Large Upper Xanthelasma Palpebrum*

Tatiana Turini, MD  
*The Use of the Orbicularis Muscle on Aesthetic Blepharoplasty*

Jorge Valentini, MD  
*A Simple Technique for Umbilicus Reconstruction with Minimal Scarring: Eight Years of Experience*

Luis Alejandro Vargas Guerrero, MD  
*Successful Treatment of Pyoderma Gangrenosum After Reduction Mamoplasty: A Case Report*

Cesar Kelly Velez, MD  
*Trans-Surgery Prophylactic Corticotherapy of Cicatricial Hiperplasia. Clinic-Estadistic Prospective Study*

Fausto Viterbo, PhD  
*New Treatment of Erectile Dysfunction After Radical Prostatectomy Using Nerve Grafts and End-To-Side Somatic-Autonomic Neurography*

Matthias Weinstock, MD, PhD  
*A Variation of Calia's Abdominoplasty Technique (1965): Abdominoplasty without Anchor Scar for Post-Bariatric Patients*

## BULGARIA

Yolanda Zayakova, MD  
*Surgical Solutions in Breast Augmentation*

## CANADA

Zeina Asyied, BSc  
*The Use of Twitter by Plastic Surgery Journals*



Eric Bensimon, MD, FRCSC  
*Facial Feminization Surgery - 16 Years Experience of 1 Surgeon*

Myriam MacDonald, MD  
*Orbital Metastasis of a Primary Cutaneous Mucinous Adenocarcinoma*

Rodrigo Neira, MD  
*Abdominal Panniculectomy and Fasciocutaneous Flap Technique for High BMI Patients and Post-Bariatric Surgery*

Kimit Rai, FRCS  
*Facial Rejuvenation with Varied Injectables*

Alex Viezel-Mathieu, MD, CM  
*Acellular Dermal Matrix Sparing Direct to Implant Prepectoral Breast Reconstruction - A Comparative Study Including Cost Analysis*

## CHILE

Stefan Danilla, MD, MSC  
*Rectus Abdominis Fat Transfer (Raft) in Lipoabdominoplasty: A New Technique to Achieve Fitness Body Contour in Patients that Require Tummy Tuck*

## CHINA

Yang An, MD  
*A Novel Technique for Short Nose Correction in Asians: Septal Cartilage Combined with Ethmoid Bone Graft*

Lei Chen, MD  
*SVF-Gel Assisted Fat Transplantation for Face Rejuvenation*

Zugen Huang, MD  
*HAI Lift (Poly-L-Lactic Acid Acetic Acid) Assisted Nasal Septal Cartilage and Auricular Cartilage in Rhinoplasty Surgery*

Ju Yun Jang, MD  
*Supratip Refinement Suture to Adjust the Supratip Contour in Aesthetic Rhinoplasty*

Yuan Li, BS  
*Exploring the Effect of Autologous Fat Granules Followed by Split-Thickness Skin on a Chronic Wound on Anterior Tibia---A Case Report*

Bailin Pan, MD  
*Upper-Lip Lift with a "T" Shaped Resection of the Orbicularis Oris Muscle for Asian Perioral Rejuvenation: A Report of 84 Cases*

Chunmei Wang, MD, PhD  
*The Value of Levator Shortening for Correction of High Supratarsal Fold After Cosmetic Upper Blepharoplasty in Asian Women*

Guanhuier Wang, MD  
*Cosmetic and Structural Outcomes of Two Different Techniques of Medial Epicanthoplasty According to Epicanthal Fold Classification and Severity: A Cohort Study*

Hongbin Xie, MD  
*Endoscopic Forehead Rhytidectomy for Patients with Upper Facial Wrinkles: Morphometric Evaluation and Patient-Reported Outcome Using Face-Q Scales*

Fang Yang, MD  
*Improvement in Patient Satisfaction and Quality of Life After Aesthetic Rhinoplasty: A Systematic Review and Meta-Analysis*

Runlei Zhao, MD  
*The Application of Costal Cartilage Harvest by Trans-Areola Approach*

Yanan Zhao, PhD  
*Construction of a Plasmid Vector Containing Epidermal Growth Factor Receptor and C-Jun ShRNA*

## CHINESE TAIPEI

Talee Chang, MD  
*Secondary Augmentation Mammoplasty: Diagnosis and Management*

Chieh Chou, MD  
*Micro-Autologous Fat Transplantation for Rejuvenation of the Dorsal Surface of the Aging Hand*

Cheng-Wei Hsiao, MD  
*Simultaneous Facelift with Facial Bone Reshaping*

Wen Hsien Ethan Huang, MD  
*Enhancing Your Rear is not Rare in China: Creating a Curvy Silhouette with New Needle-Hub Buttock Threading*

William Lao, MD  
*Optimizing Asian Periorbital Rejuvenation: Fat Injection Topography and Techniques Using an Adjustable Fat Injection Gun*

Wen-Chieh Liao, MD  
*Balanced Effect of Subbrow Upper Blepharoplasty - My Personal Experiences and Techniques*

TsaiMing Lin, PhD  
*Micro-Autologous Fat Transplantation (MAFT) for Treating a Gummy Smile*

## COLOMBIA

Ernesto Andrade, MD  
*Silicone Multi-Micro-Implants System to Increase Volumen and Reshape the Buttock*

Alfredo Hoyos, MD  
*Surgical Procedures for the Buttocks and Body*

Juan Maldonado, MD  
*New Simultaneous Harvesting and Implantation Technique in Robotic Hair Transplant*

Juan Sierra, MD  
*Lipoabdominoplasty Refinements in 5 Steps*

## COSTA RICA

Manuel Chacon, MD  
*3D Breast Augmentation Planning*

## CZECH REPUBLIC

Lubos Drazan, MD, PhD  
*Keeping Extra Skin for Future Nipple Areola Reconstruction During Mastectomy-Up Dated*

Pavel Hilbert, Ing  
*Online Communication: Errors that May Destroy Your Online Reputation*

Pavel Kurial, MD  
*The Frontal Branch of the N.VII in Relation to Face-Lift and Lateral Brow-Lift Approach*

Libor Streit, MD, PhD  
*An Innovative Device for High-Volume Fat Grafting*

## DENMARK

Stig-Frederik Kolle, MD, PhD  
*Enrichment of Autologous Fat Grafts with Ex Vivo-Expanded Adipose Tissue-Derived Stromal Cells in Cosmetic Breast Augmentation: A Randomized Controlled Clinical Trial*

Lotte Poulsen, MD  
*Body-Q: Patient-Reported Outcomes in Weight Loss and Body Contouring Surgery: A Cross-Sectional Analysis Using the Body-Q*

## ECUADOR

Francisco Borja, MD, PhD  
*Buttocks Augmentation without Prosthesis*

Hugo Jativa - Naranjo, MD  
*Lipofilling (Fat Transfer) After Cryopreservation*

## EGYPT

Aly Abulhassan, PhD  
*3D Volumetric Fat Grafting for Optimal Breast Augmentation*

Nasser Ghozlan, MD, PhD  
*Developmental Breast Asymmetry*

Tarek Raief, MD  
*Aesthetic and Functional Outcomes of Subfascial Breast Augmentation: Three Years Follow Up*

Wael Saadeleen, MD  
*Rhinoplasty for the Blurred Flabby Nose*

Mohamed Zaki, MD  
*Evolution and Updates in Rejuvenation of the Aging Face*

## FRANCE

Franck Duteille, MD  
*Ten-Year Safety Data for Eurosilicone's Round and Anatomical Silicone Gel Breast Implants (About 995 Implants)*

Foued Hamza, MD  
*Vertical Reduction Mammoplasty in Gigantomastia and Severe Breast Ptosis*

Jean Francois Pascal, MD  
*Post-Bariatric Brachioplasties: Particularities*

## GEORGIA

Konstantin Sulamanidze, MD  
*Aesthetic Appearance Removal of Face Paralytic Deformity by Thread Lifting Methods*

## GERMANY

Jens Altmann, MD  
*Early Experience with a Microwave Device for Treating Axillary Sweating in Aesthetic-Patients*

Juliana Bodo, MD  
*Optimizing the Outcome in Augmentation-Mastopexie*

Wolfgang Funk, MD  
*Presto Facelift Technique*

Stefan Hacker, MD  
*Pitfalls in the Treatment of Hemifacial Spasm and Facial Synkinesia with Botulinum Toxin*

Delia Letizia Hoppe, MD  
*Fat Grafting in Paediatric Surgery*

Kai Kaye, MD  
*Correction and Prevention of the Pixie Ear Deformity - A Combined Novel Technique Using the Posterior Earlobe Rotation Flap (PERF) and the Concha-Mastoid Suspension Suture (CMSS)*

Jens Neumann, MD  
*Our Technique to Master the Polly Beak Deformity During Rhinoplasty*

Johannes Reinmüller, MD  
*Are Silicone-Implants Chemically Active? - Impact on Biocompatibility*

Volker Rippmann, MD  
*Gluteal Fat Transplantation Gone Wrong. Early Detection and Treatment of Fat Embolism and Fat Embolism Syndrome - What Every Plastic Surgeon Needs to Know!*

## GREECE

Dimitris Agorogiannis, MD  
*Mammoplasty in the Treatment of Gigantomastia and in Balancing the Contralateral Breast in Oncoplastic Mammectomy*

Thanasis Athanasiou, MD, PhD  
*4D Vaser Hi-Def Lipo a Journey from the Past to the Future*

Christina Christoforidou, MD  
*Bodysculpting with Radiofrequency Assisted Liposuction*

Pantelis Diamantopoulos, MD  
*Immediate Breast Reconstruction using a Deepithelialized Flap from the Lower Pole of the Breast*

Evangelos Keramides, MD  
*Perfecting Aesthetic Results in Abdominoplasty: The Greek Line Technique*

Beatriz Nicaretta, MD, MSC  
*Hybrid Breast Augmentation: An Analysis of 325 Consecutive Cases*

Stavroula Rodopoulou, MD  
*Torsoplasty Using 3D Cryolipolysis. A Prospective Study Following 910 Single Sessions*

## INDIA

Kapil Agrawal, MCh (Plastic Surg)  
*Counterbalancing and Dcup: Overcoming Warping in Costal Cartilage and Producing an Ideal Dorsal Strut*

Sunil Choudhary, MS, FRCSEd, EBOPRAS  
*New 'Zisis' (Zigzag-Incision-Suction-Irrigation-System) Technique for Endoscopic Assisted Forehead Tumor Excision*

Viral Desai, MCh, DNB, MS  
*Instant Follicular Hair Unit Transplant*

Sandip Jain, MCh, FRCS (Plastic Surg)  
*Total Body Lift in Single Hospital Admission: A Panacea for Massive Weight Loss Patients?*

Monisha Kapoor, MBBS, MS, MCh  
*Use of Buccal Fat Pad for Facial Contouring*

Lokesh Kumar, MS, MCh  
*Analysis of Face Lift with Injectables*

Atul Parashar, MBBS, MS, MCh  
*Endoscopic Brow Lift in Unilateral Facial Palsy*

Sheila Rohatgi, MCh, MS, MBBS  
*Facial Rejuvenation Techniques in the Indian Scenario*

Rajesh Vasu, MBBS, MS, MCh  
*NPWT-Reducing Early Postoperative Morbidity in Giant Breast Reductions*

## IRAN

Hossein Abdali, MD  
*Relationship Between Intratracheal Pressure and Abdominal Wall Pressure in Abdominoplasty*

Hamidreza Fathi, MD  
*Histological Evaluation of the Specimens of the Aspirate Obtained from Breast Liposuction*

Mohammadhossein Hesamirostami, MD  
Supero - Septum Pedicles Mammoplasty

Hamid Karimi, MD  
Lengthening of Palate with Unilateral Buccinator Flap

#### IRAQ

Sabir Mustafa, MD  
A New Intra-nasal (Intercrural) Approach For Excision Of Hyperactive Depressor Septi Nasi Muscle

Ari Qader, PhD  
Role of Oral Propranolol in the Treatment of Infantile Hemangiomas

#### IRELAND

Fuan Chan, MD, FRCSI(Plast)  
The Innovative and Minimally Invasive Earfold Implant System (EIS) for Correction of Bilateral Prominent Ears

#### ISRAEL

Yoav Gronovich, MD, MBA  
Innovative Surgical Approach Using Mesh Sling for the Aging Neck

Eran Hadad, MD  
Submuscular Pocket Selection of Breast Silicone Implants Increase Rupture Rate

Morris Hartstein, MD  
Turning A Negative into a Positive: Correcting Eyelid Malpositions with Hyaluronic Acid Filler

Ori Shulman, MD  
Endonasal Approach for Tip Surgery: Is it Still Relevant in a World of Open Rhinoplasty

#### ITALY

Claudio Bernardi, MD  
The Aesthetic Value of the Navel in Abdominoplasty: 4 Technical Details for a Natural Look

Alfredo Borriello, MD  
Five "Key" Graft in Secondary Rhinoplasty

Domenico De Fazio, MD  
Combined Mastopexy and Augmentation with Autologous Fat Grafting: First Results with Lipopexy

Alessandro Gualdi, MD, PhD  
Minimal Undermining Suspension Technique (MUST): Combined Mid-Face and Eyebrow Lift Via Temporal Incision

Alessandro Innocenti, MD  
Tuberous Breast, A Real Challenge: A New Classification System and Personal Approach

Yuri Macrino, MD  
Complications in Aesthetic Breast Surgery: 10 Years Personal Records Review on 957 Procedures and Some Dramatic Case Presentation

Mariagrazia Moio, MD, PhD  
Our Experience With Ultralight Implants In Breast Lift After One Year Of Follow-Up

Gabriele Muti, MD  
Not Surgical Correction of Hemifacial Microsomia: Long Lasting Fillers are Suitable

Adriana Pozzi, MD  
Dorsal Aesthetic Lines in Primary Open Rhinoplasty

Giuseppe Sito, MD  
A New Proposal for a Customized Treatment of Lips

#### JAPAN

Shunsuke Nagura, MD  
Testing of Patient-Oriented Outcomes for Buccal Fat Pad Reduction Surgery

Toshihiko Satake, MD, PhD  
Dual-Pedicle Unaffected Split Breast Flap for Unilateral Breast Reconstruction with Contralateral Reduction Mammoplasty

Toshiya Yokoyama, MD, PhD  
Septal Extension Graft with Costal Cartilages Sliced in One Side

#### KOREA

Sangmo Bae, MD, PhD  
Various Applications of Non-Incisional Blepharoptosis Repair Technique

Young Hun Chung, MD  
Using Multi-Layered Resorbable Implants Via Superomedial Sulcus Approach in Medial Orbital Wall Reconstruction

Eun-Sang Dhong, MD, PhD  
Septal L-Strut Extension Graft Using Conchas in Medpor® Complications

Mingu Kang, MD, PhD  
Severe Breast Ptosis(Grade III) Correction by Various Methods

Yong Kyu Kim, MD, PhD  
Congenital Ptosis Correction With Anterior Layer Of Levator Palpebrae Aponeurosis

Seong Hwan Kim, MD  
Simultaneous Reconstruction with Nipple Sparing Mastectomy, Augmentation Mammoplasty, Mastopexy, Silicone Implant and Acellular Dermal Matrix on Polyacrylamide Gel Injected Breasts

Junwook Lee, MD  
Secondary Gluteal Augmentation: Surgical Technique and Outcomes

Seong Joo Lee, MD  
New and Economic Device that is Made Easily During Intraoperative Sustained Limited Expansion

Hyung-Sup Shim, MD, PhD  
Release of Scar Contracture with De-Epithelialized Scar Tissue Graft

Jongweon Shin, MD  
Combination Therapy Using Nonablative Fractional Laser and Intralesional Triamcinolone Injection for Keloid and Hypertrophic Scar Treatment

Insuck Suh, MD, PhD  
Simultaneous Fat Injection with Adipose-Derived Stem Cell and Foreign Body Removal as an Effective Treatment for Complications After Foreign Body Injection on Face

#### KUWAIT

Jamal Mohammad, MD, FACS  
Skin Tattoos Management with Combined Chemo/Dermabrasion Surgical Technique

#### KYRGYZSTAN

Iskender Kachkinbaev, MD  
Asian Eyelids Surgery. New Classification of the Asian Eyelids. The Anatomical Differences in the Diversity of the Asian Eyelids are Developed According to the Sagittal Section and it Determines the Type of the Operation to be Performed

#### LATVIA

Ieva Rancane, MD  
Cadaver Fat Grafts for Breast Augmentation 30 Years Follow-Up: A Case Report

#### LEBANON

Elias Nassif, MD  
Bowel Perforation and Peritonitis After Vaser Liposculpture

#### LITHUANIA

Rokas Bagdonas, MD  
Empiric Research on Patients Point of View: Key Factors in Choosing Plastic Surgery Clinic

Saulius Viksraitis, MD  
Free Diced Cartilage Grafts for Aesthetic and Reconstructive Purposes

#### MACEDONIA

Margarita Peneva, MD  
Audit of Prominent Ears Correction Using the Chong Chet Anterior Scoring Technique - Our Results

#### MALAYSIA

Sophia Si Ling Heng, MD  
Seducing the Enemy - A Novel Technique Harnessing Hypertrophic Scarring from Thermal Burn for Areolar Reconstruction

#### MEXICO

Aristides Arellano-Huacuja, MD, FICS  
Gluteoplasty, Implants and Fat Transfer Technique

Lazaro Cardenas-Camarena, MD  
Micro (MIFE) and Macro (MAFE) Fat Embolism: The Critical Difference Must Know

#### NAMIBIA

Sonia Pandey, Mch  
Peripherally De Epithelialised Umbilicoplasty Technique for Standard Abdominoplasty

#### NETHERLANDS

Wernerr Beekman, MD, PhD  
The Arc: A New Perspective on Breast Augmentation Planning

Claire de Vries, MD  
Body-Q: The Body-Q is the Best Patient-Reported Outcome Measure for Body Contouring Surgery

Maarten Hoogbegen, PhD  
Body-Q: Significant Better Health Related Quality of Life 1 Year after Abdominoplasty

Hanako Kazato, BS  
Body-Q: Improvement in Physical Function and Symptoms after Abdominoplasty

Valerie Monpellier, MD, PhD  
Body-Q - Part of the Dutch ReboC Tool

Lisa van den Berg, MD  
Body Contouring Surgery; The Key to a Better Weight Maintenance?

Emiel van Haren, MD  
How we Developed the Body-Q: A Patient-Reported Outcome Instrument for Weight Loss and Body Contouring

#### NEW ZEALAND

Michael Klaassen, FRACS  
Where Cosmetic & Reconstructive Collide: New Concepts in Congruent Facelift, Flicklift and Aesthetica

#### NORWAY

Anadi Begic, MD  
Breast Reconstruction with Autologous Tissue: Microsurgery vs Brava Fat Grafting - Prospective Comparative Study

#### PARAGUAY

Eustacio Rojas, MD  
Achieving 3D Volumization with Bichat Suspension

#### PERU

Jorge Hidalgo, MD  
Nasal Tip Projection with a Septo - Collumelar Permanent Suture: Simple, Fast and Effective

#### PHILIPPINES

Rene Valerio, MD, MBBS  
The Novel Approach to Rhinoplasty in Malays

Jesuito Zubiri, MD  
Morphology of the Malay Nose: A Subethnic Analysis of South Asian Noses

#### POLAND

Jerzy Kolasinski, MD, PhD  
Total Breast Reconstruction with Fat Grafting Combined with Tissue Expansion

Jakub Opyrchal, MS  
Body-Q: Change in the Perception of Non-Operated Areas After Body Contouring Procedure

#### PORTUGAL

Carla Brandão, MD  
The Impact of Body Mass Index on Early Postoperative Complications Following Bilateral Reduction Mammoplasty

Iris Brito, MD  
Autologous Fat Grafting for Breast Aesthetic Refinement and Oncologic Safety: Is it a Valuable or Risky Tool?

Manuel Maia, MD  
Upper Body Contouring After Massive Weight Loss: A Personal Approach

José Carlos Santos Parreira, MD  
Periorbital Rejuvenation: "Looking Better"

#### ROMANIA

Raul Chioibas, MD, PhD  
How to Avoid External Scars in Mild to Moderate Ptotic Breast Cases Using Just Anatomic Implants and Internal Tissue Manipulation

Carmen Giuglea, MD, PhD  
My Personal Opinion and Commentaries on Penile Lengthening and Thickening Procedures

Dana Jianu, MD, PhD  
One Key to Fit More Locks: Breast Pexies and Reductions With Central Inferior Pedicle with Popescu's Technique

Silviu Marinescu, MD, PhD  
Lipofilling - The Final Breast Reconstruction Method After Mammary Carcinoma

Elena Martin, MD  
Buccal Fat Pad Removal in Face Rejuvenation

Horia Siclovian, MD

*Advantages and Outcomes in Breast Augmentation Using Two Different Pocket Planes – Subfascial and Muscle Splitting Biplane*

## RUSSIAN FEDERATION

Georgiy Chemyanov, PhD

*Surgical Facial Rejuvenation After a Filament Lift (Thread-Lifting)*

Vitaly Golovach, MD

*Nasal Defect Replacement by Allogenic Cartilage*

Irina Khurstaleva, MD, PhD

*Low Bleph: Subq vs Transconj. Advantages and Disadvantages*

Oxana Kononets, MD, PhD

*My Experience in Breast Augmentation*

Kazbek Kudzaev, MD

*Waist Shaping Technique with Ribs Preservation*

Irina Marinicheva, MD

*CCL Method in Women Legs Reshaping*

Sergey Moshak, MD

*Rejuvenating Rhinoplasty Combined with Venetian Mask-Type Mid-Face Lifting*

Sergey Plaksin, MD

*Adipocyte Viability Depending on the Technique of Lipoaspiration and the Area of Fat Intake*

Sergei Shapovalov, MD

*Reconstructive Surgery in the Deformation And Defects of the Breast in Women*

Elena Sukhoparova, PhD

*Surgical Rejuvenation of the Upper Eyelids. Analysis of 1056 Cases*

## SAUDI ARABIA

Badr Abdulrauf, FRCSC

*Medicolegal Issues in Our Field*

Samira Ajmal, FRCS, FCPS (Plast), FCPS (Surg)

*Subglandular vs Subpectoral Implant Placement in Single Stage Augmentation Mastopexy*

Fuad Hashem, MD

*Superior Pedicle Mammoplasty: Personal Technique*

Mohamed Amir Mrad, MD, FRCSC, MBA, FACS

*Facial Skeletal Augmentation with PPE Chin Implants. A Video Presentation*

## SERBIA

Marija Balkovic, MD

*FUE Method - Hair Transplantation, Indications and Special Indications*

Milan Jovanovic, MD, PhD

*Contemporary Characteristics and Types of Orbital Region Ageing*

Gorana Kuka Epstein, MD

*Transplantation of Cell Enriched Adipose Tissue for Follicular Niche Stimulation in Early Androgenetic Alopecia: A Randomized, Blinded, Controlled Trial*

## SPAIN

Alexander Aslani, MD, PhD

*Body Feminization for the Male to Female Transgender Patient Using Large Volume Fat Grafting to the Buttocks*

Jesus Benito-Ruiz, PhD

*Variations of Breast Volume and Tissue Thickness After Breast Augmentation: Ultrasound and 3D Assessment*

Patricia Gutierrez-Ontalvilla, MD

*Outcomes of Lipofilling in Tuberous Breasts in Teenagers*

Marisa Manzano Surroca, MD

*2 Years Using Earfold System. What Have I Learned?*

Mario Márquez, MD

*Breast Reconstruction with Fat Grafting and Implant for Irradiated Breast Cancer Patients. Standardization of the Technique Between One, Two and Three Fat Grafts and Long Term Follow Up*

Ahmad Saad, MD, FACS

*Ethnic Rhinoplasty in Female Patients: The Neoclassical Canons Revisited*

Ana Santamaría, PhD

*Bright Eyes - Remodeling The Orbital Frame (ROF)*

## SWEDEN

Igor Niechajev, MD, PhD

*Chin Reduction*

Ebba Swedenhammar, MD

*A Five-Year Follow-Up After Repair of Abdominal Rectus Diastasis: A Prospective Randomized Study*

## SWITZERLAND

Maximilian Burger, MD

*Power-Assisted Liposuction (PAL) as an Effective Tool for the Treatment of Axillary Hyperhidrosis*

Sabri Derder, MD

*Why are We Removing Ruptured Breast Implants? A Review of the Literature*

Martin Haug, MD

*Cartilage Tissue Engineering – State of the Art and How We May Apply this Technique In Rhinosurgery in the Future*

Carlo Oranges, MD

*A Simple, Reliable, and Inexpensive Intraoperative External Expansion System for Enhanced Autologous Structural Fat Grafting*

Mathias Tremp, MD

*Outcome in Body Contouring Surgery After Massive Weight Loss – A Prospective Matched Single-Blind Study*

Simon Zimmermann, MD

*The Candy Cane Graft: Novel Tip Technique in Rhinoplasty for Ethnic Latino Patients*

## THAILAND

Kamol Pansritum, MD

*Facial Feminization Surgery: Aesthetic Concept and Surgical Technique*

Kachin Wattanawong, MD

*The Efficacy of Skin Cooling for Pain Relief During Intralesional Steroid Injection for Keloid: A Randomized Cross-Over Study*

## TUNISIA

Salma Ben Cheikh Kotti, MD

*“The Chignon Mastopexy”: A Double Glandular Suspended Flaps for an Auto-Augmentation Effect*

Jed Bouguila, MD, PhD

*Fat Grafting in Cranio-Maxillofacial Region*

Mourad Zinelabidine, MD

*Intramuscular Gluteal Augmentation: What About Long Term Results?*

## TURKEY

Hasan Celik, MD

*Aesthetic Rhinoplasty Techniques for a Frontonasal Dysplasia Deformity*

Ozlem Colak, MD

*Androgenetic Alopecia: Truth or Myth of Platelet-Rich Plasma*

Kirdar Guney, MD

*The Efficacy of Vibration Anesthesia on Reducing Pain Levels During Lip Augmentation*

Mustafa Hanci, MD

*Single Incision Gynecomastia Correction*

Cemal Alper Kemaloglu, MD

*Comparative Outcomes of Inferior Pedicle and Superomedial Pedicle Technique with Wise Pattern Reduction In Gigantomastic Patients*

Bora Ozel, MD

*Beard Restoration with Simultaneous Dermabrasion-Fue Method in Patients with Burn Alopecia*

Özay Özkaya, MD

*Autologous Breast Reconstruction with Lattissimus Dorsi Flap: Do it Easily with Five Step Formula*

Cemal Senyuva, MD

*Septum Based Upper Pole Technique for Mastopexy and Breast Reduction*

Billur Sezgin, MD

*Defining a New Variable that May Impact Long-Term Postoperative Nasal Tip Support: The Biomechanical Properties of the Columellar Strut Graft*

Erdem Tezel, MD

*Combined Scarless Approach for Aesthetic Facial Surgery*

## UKRAINE

Pavlo Denyshchuk, PhD

*Functional Principles of Closed Rhinoplasty*

Sergii Kadochnikov, MD, PhD

*From Lipofilling to Bioimplanting*

Andrii Petakh, MD

*The Regenerative Possibilities of the Fat Stem Cells. Our Experience*

Volodymyr Shapovalyuk, MD, PhD

*Endoscopic Frontotemporal Lifting – Key-Points to Better Upper Tissue Movement and «Oriental Look»*

Oleg Tkach, MD, PhD

*Correction of Congenital Asymmetries of Mammary Glands*

## UNITED ARAB EMIRATES

Venkata Ratnam Bandikatla, MCh (Plastic Surg)

*New, Small, Needle Holders: Their Designs & Usage Techniques*

Alexander Dionyssopoulos, MD, PhD

*Frostbite?! Of the Hypogastric Area of the Abdomen*

Lokesh Handa, MS, MCh

*Female Hairline Lowering with Hair Restoration*

Michael Salivaras, MD

*Multiplane Gluteoplasty. The Combination of Implants with Fat Grafting as a Powerful Technique for Refined Results*

Luiz Toledo, MD

*30 Years of the V-Tip Toledo Dissector Cannula*

## UNITED KINGDOM

Christian Asher, MBBS

*Umbilical Tailoring in Abdominoplasty: A Simple and Consistent Way of Shortening a Post Bariatric Umbilicus*

Naveen Cavale, BSc(Hons), MBBS, MRCSEd, MSc, FRCSEd(Plast)

*Safe, High Quality Breast Augmentation in the UK – An Enlarging Market*

Garrick Georgeu, MB CHB, MSc, FRCS (Plas)

*The Décolletage Area - The Bermuda Triangle of Revision Breast Augmentation Surgery*

Sandip Hindocha, MD

*The Challenges Faced When Setting Up a Plastics Hand Trauma Service in a District General Hospital within the Current NHS Economic Climate in the United Kingdom*

Nargiz Seyidova, MD

*Comparison of Patient's Satisfaction After Nipple Reconstruction and Tattooing Vs. Nipple Areolar Reconstruction and Tattooing*

## URUGUAY

Gabriella Grattarola, MD

*The Young Mouth Minimally Invasive Technique for Mouth Corner Rejuvenation*

## UNITED STATES

Turkia Abbed, MD

*Alar Base Reduction Using Cinch Suture and Nasal Sill Excision*

Husain AlQattan, MD

*Feminizing the Face: Combination of Frontal Bone Reduction and Reduction Rhinoplasty*

Mokhtar Asaadi, MD

*Comprehensive Treatment of Difficult Eyelids, Festoons and Malar Bags*

Yoav Barnavon, MD

*Breast Upper Pole Autologous Augmentation with Poly-4-Hydroxybutyrate (P4HB) Mesh Fixation*

Sophie Bartsich, MD

*Concerns about Rupture Affect Breast Implant Preferences Survey Results of 1,143 Women*

Hilton Becker, MD, FACS

*Micro Stromal Vascular Fraction Injections*

Stefanos Boukoulas, MD

*Reduction Mammoplasty Insurance Coverage and Reimbursement Guidelines Across the World: A Systematic Review*

Robert Burke, MD, MS, DDS

*Novel Use of Noncoherent Led Light for Noninvasive Body Sculpting*

William Carter, MD

*Browlift Options in the Older Patient for Visual Field Amelioration*



- Akash Chandawarkar, MD**  
*Analysis of Patient Market Dynamics for Breast and Body Contouring Using Google Trends*
- Brannon Claytor, MD**  
*Drainless Abdominoplasty with Concomitant Liposuction: How Sparing Scarpa's Fascia Enables Drain Free Body Contouring*
- Steven Cohen, MD**  
*Making Breasts More Beautiful with Fat*
- Alexandra Conde-Green, MD**  
*Assessment of Female Genital Surgery Education in Plastic Surgery Training: Reports of an Expert Opinion Survey*
- John Cook, MD**  
*Structural Mastopexy: Surgical Restoration of Breast Form*
- Grady Core, MD**  
*10 Year Experience with Minimal Access Lower Lid Recontouring*
- Steven Davison, MD, DDS**  
*Effect of Keller Funnel Use on the Rate of Capsular Contracture in Periareolar Breast*
- Riley Dean, BS**  
*Hip Asymmetry: Implications in Body Contouring Surgery*
- Barry DiBernardo, MD**  
*Treatment of Facial Acne Scars with Microneedling in Combination with Polymethylmethacrylate (PMMA)*
- Zachary Ducharme, MBA**  
*Finding a Way to Save Money and Gain Control of Your Medical Supply Procurement*
- Mathew Epps, MS, MD**  
*Breast Pocket Irrigation During Cosmetic Surgery – Current Trends in Practice*
- Jeffrey Epstein, MD**  
*The Surgical Hairline Advancement/Forehead Reduction Surgery: Indications and Technique*
- Robert Ersek, MD, FACS**  
*Safer Sedation: No Gases How Vevaket (Versed or Valium and Ketamine) can Eliminate the Dangerous Complications of General Anesthesia Gases (GAG)*
- Peter Everts, PhD**  
*Anti-Aging and Anti-Wrinkle Effects Following Pure-Platelet Rich Plasma Facial Injections: Patient Reported Outcomes Supported by Objective Biometric Evaluations*
- Sabrina Fabi, MD**  
*Optimizing Patient Outcomes Through Customization Microfocused Ultrasound with Visualization Treatments: Consensus Guidelines from an Expert Panel*
- A. J Farshchian, MD**  
*A Review Article: Neuroregeneration as an Alternative Option for the Treatment of Neurological Diseases*
- James Fernau, MD**  
*Gluteal Augmentation with Fat Grafting Using Tissue Liquefaction Liposuction: A New Method for Gluteal Augmentation*
- Danica Fiaschetti, LVN**  
*Training the Support Staff Improves the Outcome of Hyaluronic Acid Gel Related Adverse Events*
- Jared Garlick, MD**  
*Transparency of Provider Education and Board Certification Among Cosmetic Surgeons*
- Daan Geerards, MD**  
*Body-Q: The Body-Q, Could it be Shorter? Computerized Adaptive Testing of the Body-Q*
- Trina Ghosh, MD**  
*Outcomes and Revision Rates for Single and Two Stage Explantation Mastopexy Augmentation for Capsular Contracture: A Single Surgeon Experience*
- Giorgio Giatsidis, MD, PhD**  
*Closed Incision Negative-Pressure Therapy Reduces Complications in Post-Bariatric Body Contouring*
- Larry Gray, MD**  
*Experience with the MACS Facelift*
- Rachel Gray, BS**  
*How Might Juvéderm Impact a Patient's Interaction with Others?*
- Summer Hanson, MD, PhD**  
*A Randomized, Prospective, Time-and-Motion Study Comparing Rate of Processing Techniques in Autologous Fat Grafting in Breast Reconstruction*
- Narges Horriat, MD**  
*Hazards of the Harvest: Fat Grafting and Implant Related Infections*
- Dennis Hurwitz, MD**  
*Lipoabdominoplasty and Oblique Flankplasty: An Alternative to Fleur De Lys Abdominoplasty and Lower Body Lift*
- Andrey Iskornev, MD**  
*Hollywood Neck Lifting (Deep Plane Cervicoplasty)*
- Keith Jeffords, MD, DDS**  
*Automated Follicular Unit Extraction Hair Restoration*
- Charles Jehle, MD**  
*Postpartum Abdominoplasty: Addressing the Problem of Central Abdominal Soft Tissue Atrophy from Umbilical Hernia*
- Daniel Kakish, DO**  
*Can Plastic Surgeons Really Tell What Type of Implant a Patient is Wearing?*
- Shana Kalaria, MD**  
*Iatrogenic Symmastia- Etiology, Incidence, and Repair*
- Kian Karimi, MD, FACS**  
*Combining Non-Invasive Therapies for the Optimal Rejuvenation of the Face - Threads, Fillers, and PRF*
- Michael Kelly, MD**  
*The Relationship of Neo-Umbilical Design to BMI in Abdominoplasty*
- Dana Khuthaila, MD**  
*Is it Time to Dump the Drain? A Single-Surgeon Experience with Drainless Lipoabdominoplasty*
- Steve Laverson, MD**  
*Aesthetic Preference for Abdominoplasty Surface Fitness Contours*
- April Linden, BA**  
*Creating Patients for Life: Applying the Ritz Carlton Service Standards to Your Practice*
- Corey Maas, MD**  
*Escalating Doses of IncobotulinumtoxinA for Extended Treatment of Glabellar Frown Lines: Safety and Efficacy Results from a Randomized, Double-Blind Study*
- Michael Marion, MD**  
*Implant Selection in Augmentation Mastopexy*
- Gabriele Miotto, MD, MED**  
*An Algorithm for Selecting Combined Hyaluronic Acid Agents of Different Physical Properties in Facial Rejuvenation*
- Clayton Moliver, MD**  
*Transition to Non-Opioid Analgesia does not Impair Pain Control After Major Aesthetic Plastic Surgery*
- Leela Mundra, BA**  
*Mastectomy with Immediate Free Flap Reconstruction in the Obese: An Analysis of ACS-NSQIP Database*
- Narayan Nair, PhD**  
*Donut Mastopexy: Modifications for Areolar Reduction and Tuberous Breast Deformities*
- Tim Neavin, MD**  
*Eyebrow Recreation and Enhancement with Hair*
- Pablo Padilla, MD**  
*Medical Tourism and Postoperative Infections: A Systematic Literature Review of Causative Organisms and Empiric Treatment*
- Carissa Patete, BS**  
*Surgical Treatment of Symptomatic Foreign Body Injections to the Male Genitalia*
- Ivo Pestana, MD**  
*The Lateral Breast Flap Sling: A Novel Technique for Revision of Autologous Breast Reconstruction*
- Christine Petti, MD**  
*Clinical Study to Assess the SculpSure Laser for the Treatment of Contour Deformities Post-Liposuction*
- Silvio Podda, MD**  
*Refinements in Secondary Cleft Rhinoplasty. The Simultaneous Use of Multiple Grafts Reduces the Reoperation Rate Restoring Normal Anatomical Features*
- Jared Potts, MD**  
*Mycobacterium Abscessus Breast Implant-Related Infection in a Complex Patient*
- Charalambos Rammos, MD**  
*Submandibular Gland Reduction and Tangential Excision of the Anterior Belly of the Digastrics in Aesthetic Contouring of the Neck*
- Ernesto Ruas, MD**  
*The Subperiosteal Midface Lift: A 20-Year Review*
- Tim Sawyer, BA**  
*Social Media that Drives ROI*
- Claudia Sedano, MD**  
*Hernia Reconstruction in the Massive Weight Loss Patient Between 2006-2016*
- Samuel Shatkin, MD**  
*A Novel Technique for Cosmetic and Functional Correction of the Aging Nose*
- Jay Shorr, BA, CAC I-XII**  
*Your Exit Plan: Planning Ahead for Retirement*
- Mara Shorr, BS, CAC I-XII**  
*The Benefits of Proper Employee Selection: Training, Retaining and Motivating your Most Valuable Employees*
- Jacqueline Stoneburner, BS**  
*Contemporary Management of Alopecia: A Systematic Review and Meta-Analysis for Surgeons*
- Sergey Turin, MD**  
*In-Vivo Examination of Gluteal Vein Anatomy*
- Jason Tuschman, JD, MBA**  
*ROI Driven Patient Acquisition and Retention*
- Elbert Vaca, MD**  
*Identifying Aesthetically Appealing Upper Eyelid Topographic Proportions*
- Emma Vartanian, MD**  
*A Crowdsourcing-Based Assessment of Ideal Thigh Aesthetic and Implications for Gluteal Fat Grafting*
- Vasileios Vasilakis, MD**  
*Evaluating Outcomes in Venous Thromboembolism (VTE) Prophylaxis: A Comparison of Two Regimens in Abdominal Body Contouring Surgery*
- Krishna Vyas, MD, PhD, MHS**  
*Profile of Adipose-Derived Stem Cells in Obese and Lean Environments: A Systematic Review*
- Jennifer Walden, MD**  
*The Synergistic Effects of Multimodal Therapy Resulting in Better Outcomes for Women Seeking Vaginal Rejuvenation and Improvement of Sexual Function*
- Heidi Waldorf, MD**  
*Diluted and Hyperdiluted Calcium Hydroxylapatite for Skin Tightening: Guidelines from a Global Consensus Meeting*
- Elizabeth Weissler, MD**  
*Perceived Facial Aging: The Role of Ages (Advanced Glycosylation Endproducts)*
- Daniel Wong, BA**  
*Rhinoplasty Interest Around the World: An Analysis of Google User Data*
- VIETNAM**
- Hung Le, PhD, DDS**  
*Evaluation Effect of the Oro-Labial Reduction with Orthognathic Surgery*
- Ha Nguyen, MD**  
*Comparison of Endoscopic Transaxillary and Periareolar Approaches in Breast Augmentation*
- Nguyen Phan Tu Dung, PhD**  
*Surgery First Approach in Orthodontics*

## SIGN UP FOR A THREE HOUR CADAVER LAB ON WEDNESDAY

[www.ISAPSMiami2018.com](http://www.ISAPSMiami2018.com)

Chairs: Gianluca Campiglio, MD, PhD (Italy); Grady Bruce Core, MD, FACS (USA);  
Ivar van Heijningen, MD (Belgium)

### CADAVER LAB I - FACE & BROWLIFT

Instructors: Bryan Mendelson, FRCSE, FRACS, FACS (Australia),  
Carlos Casagrande, MD (Brazil), Gregory Albert, MD (USA), Chia Chi Kao, MD (USA)

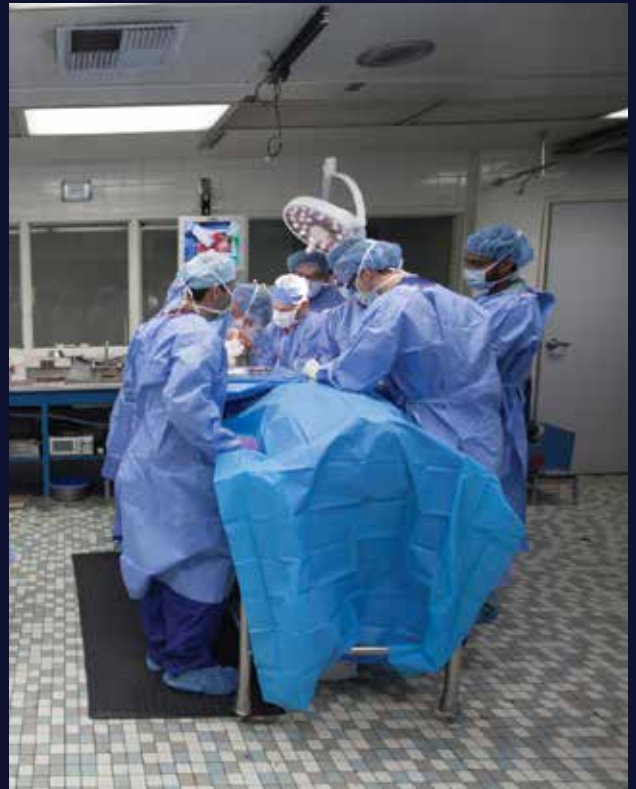### CADAVER LAB II - RHINOPLASTY

Instructors: Nazim Cerkes, MD, PhD (Turkey), Enrico Robotti, MD (Italy),  
Bahman Guyuron, MD (USA), Joseph Grysiewicz, MD, FACS (USA), Dean Toriumi, MD (USA),  
Rod Rohrich, MD, FACS (USA), Wolfgang Gubisch, MD, PhD (Germany)

### CADAVER LAB III - MASTOPEXY & LABIAPLASTY

Instructors: Lina M. Triana, MD (Colombia), Christine Hamori, MD (USA),  
Frank Lista, MD, FRCSC (Canada), W. Grant Stevens, MD, FACS (USA),  
Ruth Graf, MD, PhD (Brazil), Ricardo Ribeiro, MD (Brazil)

**SPACE IS LIMITED**



## MASTER CLASS SCHEDULE

Master Class	Wednesday	Thursday	Friday	Saturday	Sunday
	31 October	1 November	2 November	3 November	4 November
7:00 - 8:00 am					
MC1 - Face Lift	Timothy Marten	Bryan Mendelson	Foad Nahai	Daniel Baker	Mario Pelle-Ceravolo
MC2 - Brow Lift	Luis Vasconez	Stephen Perkins	Chia Chi Kao & Grady Bruce Core	Renato Saltz & Carlos Casagrande	Bahman Guyuron
MC3 - Blepharoplasty	Susumu Takayanagi	Dirk Richter & Vakis Kontoes	Glenn Jelks	Guy Massry	William Mack
MC4 - Rhinoplasty	Nazim Cerkes	Rod Rohrich	Wolfgang Gubisch	Dean Toriumi	Paul Nassif
MC5 - Breast Augmentation	Ricardo Ribeiro & Barbara Machado	Gianluca Campiglio & Giovanni Botti	Per Heden & Mark Jewell	Luis Fernando Perin & Laurie Casas	
MC6 - Breast Reduction/Mastopexy	Moustapha Hamdi	Joao Sampaio Goes	Ruth Graf	Frank Lista	James Grotting
MC7 - Abdominoplasty	Yoram Wolf	Oswaldo Saldanha	Joseph Hunstad	Ozan Sozer & Carlos Del Pino Roxo	Fabio Nahas
MC8 - Buttock Augmentation		Constantino Medieta	Alfredo Hoyos Ariza	Ashkan Ghavami & Arturo Ramirez Montanana	Raul Gonzalez
5:00 - 6:00 pm					
MC9 - Body Contouring Surgery in the MWL Patient	J. Peter Rubin	Dennis Hurwitz	Al Aly	Jean Francois Pascal	
MC10 - Hair Transplantation		Alfonso Barrera & Carlos Uebel	Jeff Epstein	Jack Fisher	
MC11 - Vaginal Rejuvenation		Lina Triana	Jennifer Walden & Christine Hamori	Khalil Khatri	Gary Alter
MC12 - How to Maximize Profit in an Aesthetic Practice		W. Grant Stevens	Jason Pozner	Robert Singer	Steven Dayan
MC13 - Strategies for Marketing & Branding your Aesthetic Practice	Catherine Maley	Karen Zupko	Gaylon McCollough	Dana Fox	
MC14 - Successful MediSpas		Jason Pozner & Renato Saltz	Louis Bucky & Laurie Casas	Julius Few & Keith Marcus	
MC15 - Non-Surgical Devices that Work for Me		Barry DiBernardo	Susan Van Dyke	Sabrina Fabi & Steven Dayan	
MC16 - Injectables that Work for Me		Haideh Hirmand & Heidi Waldorf	Joel Schlesinger	Claudio De Lorenzi	Rami Batniji

# CASE STUDY: TWO STAGE RECONSTRUCTION OF LARGE AND PTOTIC BREASTS: SKIN REDUCTION MASTECTOMY WITH PREPECTORAL DEVICE PLACEMENT



**CHARALAMBOS (BABIS) RAMMOS, MD**  
United States

## INTRODUCTION

Prosthetic reconstruction is the most common reconstructive technique following skin sparing mastectomy (SSM). The traditional approach is the placement of the device in the subpectoral plane. A concern with this approach is the risk of animation deformity and discomfort due to partial disinsertion of the pectoralis major muscle. Prepectoral reconstruction resolves many of these issues by placing the device above the muscle. Patients presenting with large and ptotic breasts remain a challenge, and skin reduction surgery is necessary at the time of reconstruction to achieve an aesthetically pleasing result.

This case describes a newer technique of immediate two-stage breast reconstruction for large and ptotic breasts. Skin reduction is performed using the Wise pattern technique while the device is placed in the prepectoral space covered completely by acellular dermal matrix and an inferior dermal flap.

## MARKINGS

Preoperative markings are similar to those for reduction mammoplasty. Because a device will be used, less skin is marked for excision. Additional skin is excised after the device has been placed as necessary. The patient is marked in the upright standing position, and the following markings are made: midline, from sternal notch to xiphoid, inframammary fold and breast meridian. The new nipple location is marked by transposition of the inframammary fold to the front of the breast, at the level of the meridian. Vertical limbs are drawn from the new nipple location. The length of the vertical limbs is tailored to each patient and for most patients is between 8-10 cm. The distance between the bottom of the vertical limbs is between 10-14 cm. The inferior ends of the vertical limbs are then joined to the inframammary fold. Measurements are made bilaterally, from sternal notch to nipple, and from midline to ensure symmetry.

## MATERIALS

All first stage reconstructions are performed with tissue expanders with suture tabs (Natrellé® 133 Tissue Expanders; Allergan, Inc., Irvine, Calif.) and 16x20 cm acellular dermal matrix (Alloderm®, LifeCell®). In the second stage, the expanders are exchanged for smooth cohesive round silicone gel implants (Natrellé Inspira® Cohesive; Allergan, Inc., Irvine, Calif.).

## FIRST STAGE TECHNIQUE

A skin sparing mastectomy is performed through use of both vertical limbs. After completion of the mastectomy, the expander is wrapped circumferentially with the 16x20 cm fenestrated Alloderm® sheet and secured to the chest wall in the prepectoral position by suturing the tabs with 2-O PDS® suture. The skin between the inferior ends of the vertical limbs and the inframammary fold is deepithelialized and fenestrated with an 11 blade knife. Inferiorly, the de-epithelialized dermal flap is draped over the expander and sutured to the Alloderm® superiorly (Figure 1). The medial and lateral skin

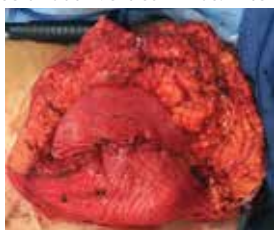

Figure 1 - Tissue expander inside the prepectoral pocket, covered completely by acellular dermal matrix and the inferior dermal flap.

flaps are draped to cover the expander, Alloderm®, and inferior dermal flap, and approximated to the inframammary fold skin edge inferiorly. Incisions are temporarily stapled and intraoperative tissue angiography assessment follows, with the use of indocyanine green. Intraoperative expansion is performed with air, and the volume injected is based on the perfusion of the flaps. The wounds are closed in a layered fashion using 3-O Monocryl® suture. Two drains per breast are routinely placed and patients are admitted at the facility for overnight observation.

## EXPANSION AND SECOND STAGE TECHNIQUE

Expansion starts in approximately three weeks, where the intraoperatively injected air is exchanged for fluid. Expansion then continues on a weekly basis. Underfilling of the tissue expanders relative to final implant placement is preferred. This allows for the placement of a larger implant in a tighter breast pocket. Expanders are then exchanged for smooth round highly cohesive implants, during the second stage of the reconstruction. Fat grafting is performed on all reconstructed breasts during implant exchange, using the Revolve® device (LifeCell®). In cases of no postoperative radiation treatment, the expanders are changed for the formal implants in eight weeks. In cases of postoperative radiation, there is a waiting period of six months after completion of the treatment, for device exchange.

## RESULT

This 44-year-old female was diagnosed with left breast cancer. She had grade 3 breast ptosis (Figure 2). During the first stage a left wise pattern mastectomy with prepectoral placement of an expander was performed (Figure 3). After a 3 month wait period, the second stage was performed. That included a right balancing breast reduction, and a left implant exchange with a 800 ml smooth round highly cohesive implant with extra projection. She was pleased with the postoperative outcome and will be undergoing nipple areola reconstruction of the left breast in the near future (Figure 4).

*The author has no financial interest in any company or product mentioned in this article.*

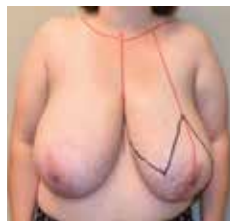

Figure 2 - Preoperative frontal view of a 44-year-old female with grade 3 ptosis.

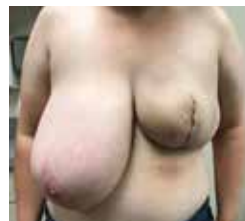

Figure 3 - Postoperative frontal image of a 44-year-old female after a left wise pattern mastectomy and placement of a tabbed tissue expander in the prepectoral space, covered by acellular dermal matrix.



Figure 4 - Postoperative frontal image of a 44-year-old female obtained at 6 months follow up after a left wise pattern mastectomy, and two stage breast reconstruction, with a right balancing breast reduction, and a left implant exchange with a 800 ml smooth round highly cohesive implant with extra projection.



# A BRIEF HISTORY OF RECONSTRUCTIVE AND AESTHETIC OTOPLASTY



**RICCARDO F. MAZZOLA, MD**  
Italy  
Associate Editor, History of Medicine

## RECONSTRUCTIVE OTOPLASTY

The first report on otoplasty for reconstructive purposes goes back to the Indian Sushruta, who lived probably around 600 BC, although there is no proof about the date (1). Repair of cleft earlobes, due to earring weight, or amputation due to trauma, were the typical indications. In the first case approximation of the margins was by cauterization, whereas in the second reconstruction was by surgery, whose details were rather unclear, apparently with a pedicled skin flap outlined on the cheek in front of the ear (2).

Defects of the ears were treated in Rome, as reported by Aulus C. Celsus (25 BC-50 AD) in *De Medicina* (On Medicine), published about 30 AD, with an advancement flap prepared and elevated for closing the wound (3). In the Byzantine period, Paulus of Aegina (625-690 AD) described management of partial ear loss in a way similar to that of Celsus (3).

During the late medieval period and in the following centuries, surgeons developed great skill in performing elective operations like cleft lip (Ambroise Paré), blepharochalasis (Georg Bartisch), and nasal restoration (Gaspare Tagliacozzi). The name of Gaspare Tagliacozzi has always been associated with the art of reconstructing noses, but this is only partially true, as he described other procedures, like restoration of auricles and lips.

Tagliacozzi was born in Bologna, Italy in 1545 and educated in a University environment. Aged 31, he was admitted to the Colleges of Medicine and Philosophy at that University and appointed Professor in 1590. He devoted himself to teach surgery to students, to give public demonstrations of anatomy and to manage surgical corrections of patients with sequelae of facial mutilations from duels, brawls, or revengeful attacks. During his life he gained considerable prestige in his profession and achieved great fame in performing reconstructive techniques. For this he is considered the founder of our specialty, Plastic Surgery (4). He died in Bologna in 1599, aged 54.

Tagliacozzi strongly opposed the general trend of the period to replace the missing parts with epithesis, avoiding any type of reconstructive procedures. The French Ambroise Paré (1510-1590), despite being an excellent surgeon, was against nasal or ear restoration with flaps. Plastic operations were twice as painful and long lasting, he argued, epithesis or caps were recommended instead. In his work *La Méthode curative des Playes & Fractures de la Teste Humaine...*, published in 1561 (5), he wrote the following about ear injuries: "In case the ear has been totally severed, once the healing has occurred completely, the patient (to mask his deformity) may wear a cap, named calotte, at the place of the ear, which will be filled with cotton or cloth, to cover the defect of the amputated ear."

Tagliacozzi wrote a seminal work *De Curtorum Chirurgia per Insitionem* (On the Surgery of Injuries by Grafting), published in Venice in 1597, where the idea of building a new nose with autologous skin harvested from the arm using a pedicled flap, was described and the step by step procedure illustrated for the first time with amazing plates (6). In this sense he should be regarded as a sort of maverick.

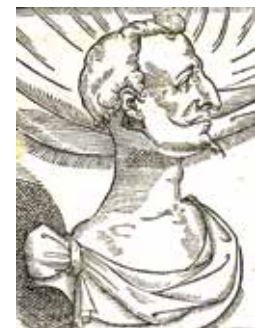In Book Two, Chapter 20, entirely devoted to the restoration of injured ears, he gave a detailed report on the reconstruction of the upper or lower third of the auricle. To the text he added two self-explanatory woodcut plates, the



Figure 1 - The bandage for post-op care following ear reconstruction (from G. Tagliacozzi, 1597)

first ones on this topic to appear in the medical literature. "The procedure consists of outlining a flap, engrafting it, treating it, and shaping it. We do not harvest this flap from the upper arm, but from the area behind the ear." He warned the reader against the hazard of raising the retro-auricular skin for the risk of bleeding. Once the flap was outlined, and hemostasis secured, the defect should be carefully handled not to damage the cartilage.

The flap was then brought into position and folded on its pedicle. In suturing it, it was recommended that the ridges and the hollows of the auricle should be respected carefully, for obtaining better healing and improving the shape. "A bandage should be made from thin, smooth cloth... The bandage runs from the vertex down to the ear, passes under it and across the throat and under the other ear and back up to the vertex, where it is tied to the other end... The straps on both sides of the face are divided into two parts at the ears. One of the divisions passes in front of the ear and the other passes behind it... The strap that is behind the ear will be used for medicating and treating the wound, while the other serves as support and stabilizes the entire bandage" (fig. 1). "The size of the defect will determine the amount of skin necessary to repair it." (fig. 2)



Figures 2a & 2b - Retroauricular flap for upper (a) and lower third (b) defect of the ear. First illustrations of a reconstructive otoplasty in the medical literature (from G. Tagliacozzi, 1597)

After Tagliacozzi reconstructive otoplasty was seldom practiced. Almost 250 years later, in the nineteenth century, the operation was rediscovered. Johann F. Dieffenbach (1782-1847) and Julius von Szymanowski (1829-1868) contributed to its development. In particular, Szymanowski in 1865 proposed a multiple flaps procedure for total ear reconstruction, which, in our opinion, has been rarely used.

## AESTHETIC OTOPLASTY

Correction of prominent ears plays an important role in the medical literature as it represents the first report of a cosmetic operation ever published. The author was Edward T. Ely (1850-1885), an ophthalmologist-otolaryngologist from New York, who published a paper in 1881 where he described in detail the management of this aesthetically unpleasant deformity on a 12-year old boy suffering from a negative psychological impact due to this anomaly (7). The operation was done in two stages, with a time lapse of 40 days between stages one and two. Ether anesthesia was administered in both circumstances. Through a posterior approach, dissection of the auricle was carried out, and an elliptical piece of cartilage with its overlying skin was excised. At the end of the procedure, the edges of the wound were approximated and sutured. At day 4, stitches were removed. Dressing consisted of cotton and bandage. Post-operative course was uneventful. The same type of operation was repeated on the contralateral side. The aesthetic result was pleasing (fig. 3).

On the other side of the Ocean, a few years later with respect to Ely, Jacques Joseph (1865-1934) was among the first to perform aesthetic otoplasty. Born in Königsberg (Prussia), Joseph began his career as an assistant to Prof. Julius Wolff, head of the University Orthopedic Clinic in Berlin, working there as an orthopaedist. One day, in 1896, a lady came to Joseph's office with her 10-year old son. The boy, much concerned for his protruding ears, didn't want to attend school anymore. The decision whether to operate the boy was not easy. Joseph had to overcome two problems. Was the Orthopaedic Clinic the correct place for an aesthetic procedure? How to obtain Prof. Wolff's approval? After a long internal debate, he carried out the procedure. Using a posterior approach, he exposed the cartilage, removed a strip from the concha, excised the excess of skin between the auricle and the scalp, sutured the wound margins and covered the ears with a heavy bandage. A few months later he proudly showed the successful result of his first plastic surgical operation at the Berlin Medical Society. Prof. Wolff, present at the meeting, did not appreciate the unauthorized procedure, and despite the outcome, he fired Joseph immediately from the Clinic. The conclusion of the first otoplasty was that the young Joseph at 31 years had to move into private practice. Initially, he dedicated



Figure 4 - Correction of prominent ears performed by Joseph about 1900. Pre- and post-op photograph (from J. Joseph, 1912)

himself to ear and nose deformities, achieving amazing results from almost every operation he undertook (fig. 4), and publishing numerous papers on these topics. In 1912, he was asked to contribute to the famed *Handbuch der Speziellen Chirurgie des Ohres und Oberen Luftwege* (Textbook of Specialistic Surgery of the Ear and Upper Airway), with numerous sketches and photographs to illustrate his chapter on Rhinoplasty and Otoplasty (8). During his professional life he did not limit his horizon to the correction of ears and nose deformities, but continuously developed new techniques of reconstructive or aesthetic nature.

It is beyond the scope of the present overview to quote the innumerable reports described over the years for aesthetic otoplasty. They range from simple skin excision in the auriculocephalic sulcus and conchal cartilage suturing to the mastoid periosteum (9), to restoration of the absent antihelix fold, basis of nearly all the surgical procedures of protruding ears correction (10), to more complex and sophisticated methods.



Figure 3 - Correction of prominent ears. Result after the first stage procedure performed on the right ear (from ET Ely, 1881)

## CONCLUSIONS

Otoplasty plays an important role in the history of Plastic Surgery whether of reconstructive or aesthetic nature. Earlobe restoration is a very old procedure carried out in India probably around 600 BC, whereas reconstruction of post-traumatic upper or lower third defects of the auricle was described and illustrated by Tagliacozzi in 1597. Correction of prominent ears, published in 1881, represents the first report of a cosmetic operation that ever appeared in the medical literature.

## REFERENCES

1. Hessler F. *Commentarii et Annotationes in Susrutae Ayuverdam*. Erlangen, Enke 1855
2. Majno G. *The Healing Hand*. Cambridge MA, Harvard University Press 1982
3. Mazzola RF, Mazzola IC. *History of Reconstructive and Aesthetic Surgery*. In: Neligan PC, Gurtner GC. *Plastic Surgery* Vol. 1. London, Elsevier 2013
4. Gnudi MT, Webster JP. *The Life and Times of Gaspare Tagliacozzi, surgeon of Bologna*. New York, Reichner 1950
5. Paré A. *La Méthode curative des Playes & Fractures de la Teste Humaine*. Paris, Royer 1561
6. Tagliacozzi G. *De Curtorum Chirurgia per Insitionem*. Venezia, Bindoni 1597
7. Ely ET. An operation for prominence of the Auricles. *Arch Otol*. (1881), 10: 97
8. Joseph J. *Korrektive Nasen- und Ohrenplastik*. In: Katz L, Preysing H, Blumenfeld F. *Handbuch der Speziellen Chirurgie des Ohres und Oberen Luftwege*. Würzburg, Kabitzsch 1912
9. Morestin H. De la reposition et du plissement cosmétique du pavillon de l'oreille. *Rev Orthop*. (1903), 4: 289
10. Luckett WH. A new operation for prominent ears, based on the anatomy of the deformity. *Surg Gynec Obst* (1910), 10: 635

## WHERE IN THE WORLD?



Answer: The Florida peninsula, with the Bahamas nearby

# IN MEMORIAM



**RICARDO BAROUDI, MD - 1932 - 2018**  
Brazil

Ricardo Baroudi, one of the most prominent Brazilian plastic surgeons, passed away on April 30 in Campinas - São Paulo. He was 85 years old. An outstanding surgeon with great skill and ability, he knew exactly how to transmit knowledge to so many surgeons from around the world who came to visit him and to see his surgical techniques for facial surgery and body contouring. He published hundreds of superb scientific papers and books that became worldwide references, especially in body contouring and post-bariatric surgery. It was his "adhesions or quilting stiches," used in large undermined flaps, for which he became definitively recognized in the plastic surgery world. As a faculty member in hundreds of national and international meetings, he delivered lectures and surgical demonstrations with extreme elegance and knowledge. For eighteen consecutive years, he was a guest speaker at the International Symposium held annually in São Paulo. He could speak fluently in Spanish, English, Italian and of course in our Portuguese language.

He was the Regional President of the Sociedade Paulista de Cirurgia Plastica, National President of the Brazilian Society (SBCP) twice, General Secretary of IPRAS and President of ISAPS from 1995 to 1997. He was also Editor-in-Chief of the Brazilian Journal of Plastic Surgery, Member of the Paulista Medicine Council and a member of many other medical and scientific societies.

Baroudi completed his medical education in 1957 at the University of São Paulo and did his training in plastic surgery with Professor Roberto Farina, one of the greatest masters at that time, where he met Merlin Kepke, one of Farina's assistants. The two founded a clinic in Campinas near São Paulo where Baroudi practiced aesthetic and reconstructive surgery. At the University of Campinas (UNICAMP) he was invited to organize a Plastic Surgery Division, where he was Professor for many years. He was a leader in our specialty organizing many national and international meetings: President of two National Brazilian Congresses; President of the IPRAS World Congress in 1979 in Rio de Janeiro; and President of the ISAPS Congress in 1997 in São Paulo.

He was married to Béa, his beloved wife and companion - a couple that radiated elegance and glamour for more than 43 years - with whom he had two children, Marcus Ricardo and Liza Beatriz, who gave them four beautiful grandchildren.

An icon of our specialty to be honored by all of us. We certainly will miss him.

*Carlos Oscar Uebel, MD, PhD*  
ISAPS Past President



**MARIANNE MÉDOT, MD - 1967 - 2018**  
Belgium

Totally unexpectedly, we received the news of the passing away of our Belgian colleague, ISAPS member Marianne Médot at the age of 51.

She studied medicine in Liège, Belgium and graduated as a Plastic Surgeon in 1999. She moved to the United States for two years where she studied at the University of Minnesota in Minneapolis then in Birmingham (UK). During this period, she gave birth to two children.

After returning to Belgium, and having a third child, she started working in Liege and Huy. In 2009, she moved to Knokke where she worked at Duinbergen Clinic and in the AZ Zeno hospital which she combined with her work in the Botaclinic in Liege and the hospital of Huy.

We remember her as a conscientious, serious and ethical surgeon with a big heart for her patients. She will be missed dearly by all who worked with her. We wish her family and friends strength in this difficult time.

*Ivar van Heijningen and Jean-Luc Nizet*





**GAITH SHUBAILAT, MD - 1939-2018**  
Belgium

Jordan lost a pioneer and a great man this year. He was laid to rest after a military final salute for a Major General in the Armed forces, surrounded by his loving family and friends. Born on a hot winter day on November 1939 in Baghdad, to an influential political Jordanian family, and being the eldest of six children, Dr. Shubailat would find himself amongst the top in his class. He would later enrol in the army to secure a medical scholarship to St. Mary's Hospital, London University (1962). He then completed his internship and basic surgical training at the main Royal Army Hospital in Amman.

Dr. Shubailat was a quiet man in public, unless you caught him where he was most comfortable - in the operating theatre. There he would recite many of his heroic lifesaving stories and his passion for the field that he helped create in Jordan.

In his junior days in the army hospital, after completing his FRCS in London, he would find himself immersed in all kinds of surgical cases at the hospital; however, the plastic and reconstructive cases in particular managed to seek him out. He was introduced to the field by one of his seniors, and he clearly enjoyed it from the very beginning. When he got the chance to solidify his passion, he took the opportunity by spending two years at Georgetown University and went on to become the first Jordanian to be American Board certified in plastic and reconstructive surgery in 1975.

Dr. Shubailat hit the ground running and quickly began elevating the field in Jordan, making the royal medical services of the army a world class plastic surgery unit. He established the first training program in the region which to this day stands as one of the most comprehensive programs in the field and has since graduated over 40 fellows.

Dr. Shubailat was keen on learning all aspects of the field and this was clearly shown in his operative records. He performed over 1,200 hypospadias cases (which he learned from Charles Horton), 1,000 cleft lip/palate cases, and he was the first to use the microscope for free tissue transfers. Before going into the operating room, he would often remember all the challenges that he met in the earlier days of plastic surgery, and the many direct encouraging conversations that he had with King Hussein of Jordan - the greatest supporter of the Royal Medical Services.



*The author with Dr. and Mrs. Shubailat in Bergamo, Italy.*

However, none of these cases would compare to what he went through when his son accidentally severed the forearm of a young girl in the south of Jordan during a boating accident. He would often say "this was the most difficult case and most difficult time of my life." Showing his perseverance, he operated on the girl over 18 times and was granted all the medical attention he needed. Needless to say, due to his brilliance and commitment, the arm was saved, and the young girl went on to live a normal healthy life.

In 1983, Dr. Shubailat retired from the army to pursue a career in private practice, and more importantly focus on the single procedure that would come to define his prolific career: rhinoplasty. He performed over 6,000 closed rhinoplasties, until he met Dr. Jack Gunter during a course in 1988. He said to me: "That advanced rhinoplasty course would change my life." He went on to perform over 8,000 open rhinoplasties, including his favorite, secondary rhinoplasties.

I first met him in 1988 when he gave a lecture about plastic surgery on careers day. His clarity, passion and mild mannerism instantly captured me, and I never wanted to be anything else. I was a 12-year old boy. This tremendous charisma would always separate him from his peers. His voice of wisdom, self-respect, and decency made us view him as the Godfather of Jordanian plastic surgery.

Dr. Shubailat's gradual climb on the international scene was at first incremental, but he made his splash in the early 2000's when he was invited to India as a speaker. There he would perform live surgery in front of hundreds of plastic surgeons, and the moderator at the time was Dr. Thomas Biggs who said: "that was the best rhinoplasty dissection I have ever seen in my life." From then on, he would be invited to many international meetings and became a permanent fixture on any rhinoplasty meeting. He had an endless passion for plastic surgery, often telling me: "I wish I had your age and my experience, so I could further push this field."

Dr. Shubailat loved the cinema and great movies. He often played movie theme songs while operating. He also had a passion for tennis and sports cars.

Dr. Shubailat's operating room was always open and he welcomed young ambitious plastic surgeons. His initial health mishap would occur while he was in his "home," the operating room, doing what he loved most. Dr. Shubailat left us on a cold summer day in May 2018.

Lost, but never duplicated and certainly never forgotten, Dr. Shubailat is survived by his son Zeid, daughters Nadine and Haya, his wife Zein and five siblings.

*Shawkat Sati, MD*  
Amman, Jordan

The background of the advertisement is a vibrant, multi-colored powder explosion. The colors transition from deep blue and purple at the top, through yellow and orange in the middle, to bright pink and red at the bottom. The particles are fine and densely packed, creating a sense of movement and energy. In the top right corner, there is a dark grey rectangular box containing the Merz Aesthetics logo.

MERZ AESTHETICS®

Inspired  
by you

Your Practice.  
Your Patients.  
Our Priority.

You're listening to patients. We're listening to you.

Now we're introducing an expanded suite of products, procedures and support to help you address a full range of patient and practice needs for the face, neck, décolletage, hands and more.

Learn more at [merz.com](http://merz.com)



[WWW.ISAPSMIAMI2018.COM](http://WWW.ISAPSMIAMI2018.COM)

The New Miami Beach Convention Center





# ISAPS WELCOMES NEW MEMBERS

MARCH THROUGH MAY 2018

## ARGENTINA

Jose BANDEO, MD  
Myrian DE ROSA, MD  
Nestor MANADER, MD\*\*  
Miguel PUGA, MD\*\*

## AUSTRALIA

Robert KNIGHT, MBBCh, MD, MRCS, FRACS(Plast)  
Mansoor MIRKAZEMI, BMedSci, MBBS, FRACS(Plast)  
Alexandra O'NEILL, MBBS (Flinders)\*\*  
Richard ZINN, MD\*

## AUSTRIA

Janos CAMBIASO-DANIEL, MD\*\*  
Peter DURNIG, MD  
Bernd SCHUSTER, MD  
Paul WURZER, MD, MMS\*\*

## BELARUS

Dmitry LADUTKO, MD

## BRAZIL

Juan ARBELÁEZ, MD\*\*  
Astrid ARDILA, MD\*\*  
Sergio Andres AREVALO, MD\*\*  
Leonardo Xavier BRAGA, MD\*  
Miluska BROMLEY, MD\*\*  
Tamsin BURGUES, MBBS\*\*  
Geraldo Andrade CAPUCHINHO JUNIOR, MD\*  
Carlos CASAGRANDE, MD  
Jairo CASALI, MD\*  
Luciana CASTRO, MD\*\*  
Andre Gonçalves de Freitas COLANERI, MD  
Fábio CUNHA, MD  
Marco Tulio Rodrigues CUNHA, MD, PhD  
Arthur Koerich DAVILA, MD\*  
Joao Pedro ESTIMA DE SOUZA, MD\*\*  
Vivian FERRARI, MD\*\*  
Thiago Alessandro FERRI, MD\*  
Luma GUARESCHI, MD\*\*  
Frederico Inácio GUIMARÃES, MD\*  
Juan Camilo HOLGUIN, MD\*\*  
Thomaz Santos LYRA, MD\*  
Henrique Figueiredo MARQUEZINE, MD\*  
Maria MARTINS, MD  
Paulo Roberto da Silva MENDES, MD  
Heloisa MENEZES, MD\*\*  
Guilherme Bussade MONTEIRO DE BARROS, MD  
Andre Alencar MOREIRA, MD  
Deisy MOSQUERA PALOMEQUE, MD\*\*  
Patricia Maria Araujo NEVES, MD  
Alexandre NUNES, MD  
Vinicius OLIVEIRA, MD\*  
Guilherme PINTARELLI, MD\*  
Felipe Kunrath Simões PIRES, MD  
Joaquín RAMIREZ, MD\*\*  
Daniel REIS, MD  
Rafael Vilela Eiras RIBEIRO, MD\*\*  
Ronaldo RIGHESSE, MD  
Paolo ROCHA, MD  
Franz ROJAS, MD\*\*  
Karen ROMERO, MD\*\*  
Marina ROSIQUE, MD

José Aurino Cavalcanti SARAIVA, MD  
Lara Catarine de Luca Maciel SCHÜLER, MD  
Hector SERRANO REYES, MD\*\*  
Diego Machado SILVANO, MD\*  
Ody SILVEIRA Jr., MD\*  
Ricardo SILVEIRA, MD  
Tiago Sarmento SIMAO, MD\*  
Marcos Antenor STORION Jr., MD\*\*  
Santos Arismendy WINSTON DARWIN, MD\*\*

## CANADA

Sarah AL YOUHA, MB ChB, PhD, FRCS(C)\*\*  
Tassos DIONISOPOULOS, MD, CM, FACS, FRCS(C)  
Wisam MENESI, MD, FRCS(C)  
Stanley VALNICEK, MD, FRCS(C)

## CHINA

Runlei ZHAO, MD

## CHINESE TAIPEI

Tsang-Shan CHER, MD  
Yu-Hao HUANG, MD

## COLOMBIA

Jorge MEJÍA CAÑAS, MD  
Carlos Alberto VELASCO ECHEVERRI Sr., MD

## DOMINICAN REPUBLIC

Carlos Adolfo GONZÁLEZ CORTORREAL, MD\*  
Jose Luis PLAZA, MD\*

## ECUADOR

Luis Alberto TINOCO CAZORLA, MD\*

## ESTONIA

Heiko ATNA, MD\*\*  
Mart ELLER, MD  
Isabella-Gabriela HEIDO, MD\*\*  
Pille KIRJANEN, MD  
Katrin KRUUNVALD, MD  
Juri KULLAMAA, MD  
Mare MALVA, MD  
Anastassia SERTSENKOVA, MD\*\*  
Siim SIMMO, MD  
Olavi VASAR, MD  
Triin VASAR, MD

## FRANCE

Fatemeh Sohi AFKHAMI AGHDA, MD  
Nordine BENYACOUB, MD  
Thomas COLSON, MD  
Vincent DELLIÈRE, MD  
André ELIA, MD, PhD  
Jérémy LAMY, MD  
Francois MILLET, MD  
Arnaud PETIT, MD\*  
Florence RAMPILLON FOUQUET, MD  
Stéphane RAOULT, MD  
Etienne SIMON, MD, PhD

## GERMANY

Allan A. ALLAN, MD, PhD  
Sixtus ALLERT, MD  
Jens ALTMANN, MD  
Sebastian Tobias BERENDES, MD, PhD

Christoph BIEGANSKI, MD\*  
Melodi MOTAMEDI, MD\*

## HONDURAS

Luis Alberto GONZALEZ-FERNANDEZ, MD

## INDIA

Kapil AGRAWAL, MBBS, MCh  
Shrirang Ganapati PANDIT, MBBS, MS, MCh  
Lukesh Arun PATIL, MD\*\*

## INDONESIA

Arviansyah ARVIANSYAH, MD  
Indri Lakhsmi PUTRI, MD  
Herman Yosef Limpat WIHASTYOKO, MD

## ISRAEL

Boaz AMAN, MD  
Noam ARMON, MD  
Tomer AYZENBERG, MD\*  
Avner BENSOUSSAN, MD  
Alexander BEREZOVSKY, MD, PhD  
Yoav EROS, MD  
Nimrod FARBER, MD  
Yosef FICHMAN, MD  
Nir GAL OR, MD\*  
Yoav GRONOVICH, MD  
Tamar HALPERIN BEN-AMI, MD\*\*  
Michael ICEKSON, MD  
Hadar ISRAELI BEN-NOON, MD\*  
Shokrey KASSIS, MD  
Ehud MAOR, MD\*  
Benjamin MELLIK, MD  
Oanna MEYER, MD  
Shira SHOMER, MD\*  
Ron TENZER, MD, PhD  
Ariel TESSONE, MD  
Anitta VILAN, MD  
Omer WOLF, MD\*

## ITALY

Paolo Angelo Alberto FUMAGALLI, MD  
Andrea PARAFIORITI, MD\*\*  
Igor PELLEGGATTA, MD\*\*

## JAPAN

Minako FUKUZAWA, MD  
Toshitsugu HIROHI, MD  
Toshiya YOKOYAMA, MD, PhD

## LATVIA

Ieva RANCANE, MD\*\*

## MALAYSIA

Sophia Si Ling HENG, MD\*\*

## MEXICO

Rubén AGREDANO JIMÉNEZ, MD  
Saúl A. ARJONA RODRÍGUEZ, MD  
Francisco AVILA ARAUJO, MD  
Armando BRISEÑO, MD  
Rodrigo CAMACHO ACOSTA, MD  
Romeo C. CASTILLO MORENO, MD\*  
Humberto COTA SOLTERO, MD\*\*

Adrian DE LEON JASSO, MD\*  
Julio Cesar DIAZ BARRIGA, MD\*\*  
Imelda DIAZ RUIZ, MD\*  
Emmanuel A. FLORES GONZALEZ, MD  
Mauricio GARCIA LOPEZ, MD\*  
Jesus HERRERA PACHECO, MD  
Carlos Alejandro MOLINA VILLA, MD  
Maria de Lourdes ORTEGA CAUDILLO, MD  
Rodolfo L. RIOS LARA Y LOPEZ, MD\*  
Rolando E. SAMPER MENDOZA, MD  
Raul TRUJILLO MENDEZ, MD\*

## MOROCCO

Souad AIMAD EDDINE, MD  
Ghani AKTOUF, MD  
Naima BAHECHAR, MD  
Siham BELHAMA, MD  
Rhizlaine BELLEFQIH, MD  
Hassan BEN MOUSSA, MD  
Amina BENBRAHIM, MD  
Amine BOUAICHI, MD  
Mounia DIOURI, MD  
Hatim DROUSSI, MD  
Sanaa EL MOUNJID, MD  
Nahed FATHI AHMED, MD  
Abdellatif HIROUAL, MD  
Mustapha IBNOUZAHIR, MD  
Amine KHALES, MD  
Saad LAHMITI, MD  
Wafaa MRADMI, MD  
Safa OUAHBI, MD  
Karima RAHMOUNI EL IDRISSE, MD  
Maria REGHAI, MD  
Souad TERRAB, MD

## NORWAY

Anadi BEGIC, MD  
Christian TILLER, MD  
Tyge TINDHOLDT, MD, PhD

## PERU

Rosa ANGULO, MD\*  
Bernardo FLORES, MD\*  
Leyla MELENDEZ, MD\*  
Rafael ROSSI, MD\*

## PHILIPPINES

Dino Fernandez BUENAVENTURA, MD\*\*  
Lisa Marie Canapi JAYME, MD\*\*

## POLAND

Tomasz DEBSKI, MD, PhD  
Alina HEDRYCH-OZIMINA, MD\*  
Piotr JANIK, MD  
Tomasz SIREK, MD, PhD\*  
Piotr Jakub TURKOWSKI, MD\*\*

## PORTUGAL

Carla BRANDÃO\*\*  
Nuno Correia Louro FRADINHO, MD  
Alice PEREIRA, MD

## ROMANIA

Filip ARDELEAN Sr., MD  
Andrei Paul COVACI, MD\*  
Ina PETRESCU, MD  
Cristian VANCEA, MD\*\*  
RUSSIAN FEDERATION  
Ilia ALMAZOV, MD\*  
Georgiy CHEMYANOV, MD, PhD

## SAUDI ARABIA

Badr ABDULRAUF, MD, FRCS  
Yahya Essa ABUAMARA, MD  
Mamdooh Abdulaziz ASHY, MD  
Samir AWAAD, MBBCh, FRCS  
Nadiyah Hussein BUNDUGJI, MD, FRCS  
Ahmed ELSISSY, MD, PhD

## SERBIA

Ivan JOVANOVIĆ, MD\*\*  
Igor MALJKOVIĆ, MD  
Dejan NOVAKOVIĆ, MD

## SOUTH AFRICA

Dimitri LIAKOS, MD\*

## SOUTH KOREA

Sangmo BAE, MD, PhD  
Eun-Sang DHONG, MD, PhD  
Seung Wook SONG, MD

## SPAIN

Obdulia CANADAS-MORENO, MD  
Arturo Jose CARBONELL, MD  
Maria CARTAGENA, MD  
Maria Jose Sanchez GARCIA, MD  
Susana LOPEZ DIAZ, MD  
Rosario PINAL GOBERNA, MD  
Julio TERREN RUIZ, MD  
Maria YAGUES, MD, PhD

## THAILAND

Wichuda LERTPANYA, MD, PhD  
Surawej NUMHOM, MD  
Kachin WATTANAWONG, MD

## TUNISIA

Jed BOUGUILA, MD, PhD

## TURKEY

Ali ALIYEV, MD  
Zafer ATAKAN, MD  
Serdar Bora BAYRAKTAROGU, MD  
Omer BUHSEM, MD  
Mert DEMIREL, MD  
Kamran EFENDIOGLU, MD  
Burak ERSOY, MD  
Ayla Emine GOKCE, MD  
Eda ISIL, MD, FEBOPRAS  
Emine Cigdem KARADAG, MD  
Eksal KARGI, MD  
Cemal KEMALOGLU, MD  
Ersoy KONAS, MD  
Bora OK, MD  
Ali Riza ÖREROĞLU, MD  
Sema OZDEN, MD  
Guncel OZTURK, MD  
Billur SEZGIN, MD  
Alpaslan TOPCU, MD  
Serhat TOTAN, MD  
Çağlayan YAĞMUR, MD

## UKRAINE

Sergiy GAVRYLENKO, MD

## UNITED KINGDOM

Marcus DAVIS, MD, FRCS(Plast)\*  
Sofiane RIMOUCHE, MD  
Rohit SETH, MD\*

## UNITED STATES

Ahmed AFIFI, MD  
Faris Abdulrahman ALDAGHRI, MBBS, SBPS  
Anuja K. ANTONY, MD, MPH, FACS  
Edgar BEDOLLA, MD\*\*  
Stefanos BOUKOVALAS, MD\*\*  
Timothy M. BRADLEY, MD  
Mauricio CASTELLON, MD, FACS  
Taylor CRIST, MD  
Cecilia A. CUESY, MD  
Riley DEAN, MD\*\*  
Jeena EASOW, MD\*\*  
Mathew EPPS Jr., MD\*\*  
Jordan D. FREY, MD\*\*  
Jared GARLICK, MD\*\*  
David GERTH, MD\*\*  
Kriya GISHEN, MD\*\*  
Mirtha GONZALEZ, MD\*\*  
Sarah HAMMOND, MD\*\*  
Shana KALARIA, MD\*\*  
Karen KAPLAN, MD\*\*  
Seung Ah LEE, MD\*\*  
Anne-Sophie LESSARD, MD\*\*  
Tobias LONG, MD\*\*  
Prakash MATHEW, MD\*\*  
Patricia Ann MCGUIRE, MD  
John MESA, MD  
Michael MIRMANESH, MD\*\*  
Juan ORTIZ, MD  
Steven OVADIA, MD\*\*  
Mark PETERS, MD  
Otto PLACIK, MD  
Michael PLASTINI, MD\*\*  
Leif ROGERS, MD, FACS  
Ernesto RUAS, MD  
David SAHAR, MD, FACS  
Sriram SANKARANARAYANAN, MD\*\*  
Borja SANTAELLA-SANTE, MD\*\*  
Ira L. SAVETSKY, MD\*\*  
Mark A. SCHUSTERMAN II, MD\*\*  
Piotr P. SKOWRONSKI, MD\*\*  
Sharon STANLEY, MD\*\*  
Patricia TESCHKE, MD\*\*  
Seth THALLER, MD  
Tuan Anh TRAN, MD\*  
Natalia VIDAL LAUREANO, MD\*\*  
Krishna VYAS, MD, PhD, MHS\*\*  
Tony WEAVER, DO\*\*  
Luccie WO, MD\*\*  
Lauren WRIGHT, DO\*\*  
Jason YOO, MD\*\*  
Joshua D. ZUCKERMAN, MD, FACS

## URUGUAY

Anna Gabriella GRATTAROLA, MD

## VENEZUELA

Desireé CELIS, MD\*\*  
Marisela CEMBORAIN, MD  
Carlos Luis MORENO-PINEDA, MD  
Omar Enrique ORSINI, MD\*

\* indicates Associate Member

\*\* indicates Associate Resident/Fellow Member

# MEETINGS CALENDAR



## MIPSS 2018 - Marbella International Plastic Surgery Summer School

Date: 21 June 2018 - 23 June 2018

Location: Marbella, SPAIN

Contact: Dr. Kai Kaye

Email: [info@oceanclinic.net](mailto:info@oceanclinic.net)

Tel: 34-951-775518

Website: <http://www.mipss.eu/>



## High Definition Liposculpting Using the PAL MicroAire System Master's Course

Date: 19 July 2018 - 20 July 2018

Location: Barcelona, SPAIN

Contact: Dr. Ahmad Saad

Email: [drsaad@institutodebenito.com](mailto:drsaad@institutodebenito.com)

Tel: 34-932-530282

Website: <https://www.institutodebenito.com/pal-high-definition-masters-course/>



## First International Aesthetics and Art Meeting

Date: 10 August 2018 - 11 August 2018

Location: Zurich, SWITZERLAND

Contact: Dr. Mathias Tresp

Email: [mtresp@me.com](mailto:mtresp@me.com)

Tel: 41-44-211-8260

Fax: 41-44-212-8203

Website: <http://www.swissaesthetics.ch>



## ISAPS Course - Turkey, 10th Eurasian International Aesthetic Course with Live Surgeries

Date: 21 June 2018 - 24 June 2018

Location: Istanbul, TURKEY

Contact: Yagiz Tutuncuoglu

Email: [yagiz@seveneventcompany.com](mailto:yagiz@seveneventcompany.com)

Tel: +90-5337471423

Website: <http://eurasian2018.org/>



## ISAPS Symposium - Chile

Date: 27 July 2018 - 28 July 2018

Location: Santiago, CHILE

Contact: Dr. Montserrat Fontbona

Email: [mfontbona@yahoo.com](mailto:mfontbona@yahoo.com)

Tel: 56-2-331-7025

Fax: 56-2-220-7722



## Plastic and Aesthetic Surgery Meeting (PASM) 2018

Date: 30 August 2018 - 01 September 2018

Location: Singapore, SINGAPORE

Contact: Ms Chandrakala D/O Krishnasamy

Email: [pasm@ams.edu.sg](mailto:pasm@ams.edu.sg)

Tel: 65-937868

Website: <https://www.pasm2018.com/>



## 11th Post-Bariatric Body Contouring Course by J. F. Pascal, MD

Date: 29 June 2018 - 30 June 2018

Location: Geneva, SWITZERLAND

Contact: Geraldine Buffa

Email: [geraldine@ipsac.eu](mailto:geraldine@ipsac.eu)

Tel: +33 4 78 24 59 27

Website: <http://www.ipsac.eu>



## 37th Jornada Carioca de Cirurgia Plastica & ISAPS in Rio

Date: 01 August 2018 - 04 August 2018

Location: Rio de Janeiro, BRAZIL

Email: [sbcprj@openlink.com.br](mailto:sbcprj@openlink.com.br)

Tel: +55(21) 2266-7821

Website: [www.sbcprj.org.br](http://www.sbcprj.org.br)



## ISAPS Course - China

Date: 06 September 2018 - 07 September 2018

Location: Shandong Province, CHINA

Contact: Dr. Li Yu

Email: [yuoli@163.com](mailto:yuoli@163.com)

Tel: 86-21-6313-5715

Fax: 86-21-5307-8025



## ISAPS Symposium - Indonesia - immediately preceding the OSAPS meeting

Date: 18 July 2018

Location: Bali, INDONESIA

Contact: Dr. Theddeus O. H. Prasetyono

Email: [teddyohp@yahoo.com](mailto:teddyohp@yahoo.com)

Tel: 62-21-31931424

Fax: 62-21-3193142424

Website: [www.osaps-inapras.org](http://www.osaps-inapras.org)



## ISAPS Symposium - NEW ZEALAND

Date: 02 August 2018

Location: Auckland, NEW ZEALAND

Contact: Dr. Morris Ritz

Email: [morris@melbplastsurg.com](mailto:morris@melbplastsurg.com)

Tel: 61-3-9508-9508



## 5th São Paulo Breast Symposium

Date: 14 September 2018 - 15 September 2018

Location: São Paulo, BRAZIL

Contact: Dr. Joao Sampaio Goes

Email: [clinica@sampaio Goes.com](mailto:clinica@sampaio Goes.com)

Tel: 55-11-3167-2200

Website: <http://spbs.com.br/>





### High Definition Liposculpting Using the PAL MicroAire System Master's Course

Date: 20 September 2018 - 21 September 2018  
Location: Barcelona, SPAIN  
Contact: Dr. Ahmad Saad  
Email: [drsaad@institutodebenito.com](mailto:drsaad@institutodebenito.com)  
Tel: 34-932-530282  
Website: <https://www.institutodebenito.com/pal-high-definition-masters-course/>



### Live Plastic Surgery – State of the Art

Date: 20 September 2018 - 22 September 2018  
Location: Monte-Carlo, MONACO  
Contact: Dr. Henry Delmar  
Email: [henry@henry-henrydelmar.com](mailto:henry@henry-henrydelmar.com)  
Tel: 33-04-93670101  
Website: [www.liveplasticsurgery-monaco.com](http://www.liveplasticsurgery-monaco.com)



### CATBBAS IV

Date: 21 September 2018 - 23 September 2018  
Location: Brussels, BELGIUM  
Contact: Cindy Nuyts  
Email: [cindy.nuyts@uzbrussel.be](mailto:cindy.nuyts@uzbrussel.be)  
Tel: 32-2-474-9400  
Fax: 32-2-477-6250  
Website: <http://www.brussels-seminars.com/>



### ISAPS Course – Brazil

Date: 28 September 2018 - 29 September 2018  
Location: Porto Alegre, BRAZIL  
Contact: Dr. Marcelo Maino  
Email: [contact@isapsinportoalegre.com.br](mailto:contact@isapsinportoalegre.com.br)  
Tel: 55-51-32166300  
Website: <http://www.isapsinportoalegre.com.br>



### Breast Augmentation Course

Date: 06 October 2018  
Location: Live streamed surgery, no physical attendance  
Contact: Dr. Carlo Gasperoni  
Email: [olympoeducational@gmail.com](mailto:olympoeducational@gmail.com)  
Tel: 39-3356994025  
Website: <https://www.olympoeducational.com/>



### ISAPS Symposium – United Kingdom

Date: 06 October 2018  
Location: London, UNITED KINGDOM  
Contact: Aleiya Lonsdale  
Email: [aleiya.lonsdale@easyfairs.com](mailto:aleiya.lonsdale@easyfairs.com)  
Tel: +44 (0) 20 3196 4375  
Website: [www.isaps-symposium.co.uk](http://www.isaps-symposium.co.uk)



### IMRHIS 2018

Date: 29 October 2018 - 31 October 2018  
Location: Miami Beach, FL, UNITED STATES  
Contact: Susan Russell  
Email: [russell@hdplanit.com](mailto:russell@hdplanit.com)  
Tel: 1-435-602-1329  
Fax: 1-435-487-2011  
Website: <http://www.IMRHIS2018.com>



### 24th Congress of ISAPS

Date: 31 October 2018 - 04 November 2018  
Location: Miami Beach, FL, UNITED STATES  
Contact: Catherine Foss  
Email: [isaps@isaps.org](mailto:isaps@isaps.org)  
Tel: 1-603-643-2325  
Fax: 1-603-643-1444  
Website: <http://www.isapsmiami2018.com/>



### Endoscopic Transaxillary Breast Augmentation Hands-on Workshop on Fresh Human Species and Live Surgery

Date: 09 November 2018 - 10 November 2018  
Location: Vienna, AUSTRIA  
Contact: Dr. Kloppel & Kollegen  
Email: [training@drkloppel.com](mailto:training@drkloppel.com)  
Tel: 49-89-79070780  
Fax: 49-89-79070727  
Website: <https://www.drkloppel.com/en/training/>



### Second Global Masters Aesthetic Symposium

Date: 13 November 2018 - 16 November 2018  
Location: Tehran, IRAN  
Contact: Bahman Guyuron  
Email: [bguyuron@guyuron.com](mailto:bguyuron@guyuron.com)  
Tel: +1.440.646.1279  
Fax: +1.440.461.4713



### High Definition Liposculpting Using the PAL MicroAire System Master's Course

Date: 15 November 2018 - 16 November 2018  
Location: Barcelona, SPAIN  
Contact: Dr. Ahmad Saad  
Email: [drsaad@institutodebenito.com](mailto:drsaad@institutodebenito.com)  
Tel: 34-932-530282  
Website: <https://www.institutodebenito.com/pal-high-definition-masters-course/>



### ISAPS Course – Vietnam

Date: 07 December 2018 - 09 December 2018  
Location: Ho Chi Minh City, VIETNAM  
Additional Details Pending

## ISAPS EXECUTIVE OFFICE STAFF

---

45 Lyme Road, Suite 304  
Hanover, NH, USA 03755  
Phone: 1-603-643-2325  
Fax: 1-603-643-1444  
Email: [ISAPS@isaps.org](mailto:ISAPS@isaps.org)  
Website: [www.isaps.org](http://www.isaps.org)

### EXECUTIVE DIRECTOR

Catherine Foss  
[ISAPS@isaps.org](mailto:ISAPS@isaps.org)

### ABSTRACT MANAGER

Jodie LeBrun  
[Abstracts@isaps.org](mailto:Abstracts@isaps.org)

### FINANCE OFFICER

Sally Rice  
[Accounting@isaps.org](mailto:Accounting@isaps.org)

### MEMBERSHIP SERVICES MANAGER

(Ms) Jordan Carney  
[Membership@isaps.org](mailto:Membership@isaps.org)

### EDUCATION EVENTS MANAGER

Michele Nilsson, CMP  
[Registrar@isaps.org](mailto:Registrar@isaps.org)

## ISAPS NEWS MANAGEMENT

---

### EDITOR

J. Peter Rubin, MD, FACS (United States)

### ASSOCIATE EDITOR, HISTORY OF MEDICINE

Riccardo Mazzola, MD (Italy)

### MANAGING EDITOR

Catherine B. Foss (United States)

### CHAIR, COMMUNICATIONS COMMITTEE

Arturo Ramirez-Montanana, MD (Mexico)

### CHIEF MARKETING OFFICER

Julie Guest (United States)

## ISAPS BOARD OF DIRECTORS, COMMITTEE CHAIRS & APPOINTMENTS 2016 – 2018

---

### Board of Directors

President	Renato Saltz, USA
President-Elect	Dirk Richter, Germany
1st Vice President	Nazim Cerkes, Turkey
2nd Vice President	Lina Triana, Colombia
3rd Vice President	Grant Stevens, USA
Secretary	Gianluca Campiglio, Italy
Treasurer	Kai Schlaudraff, Switzerland
Historian	Tom Davis, USA
Parliamentarian	Arturo Ramirez-Montanana, Mexico
National Secretaries Chair	Peter Scott, South Africa
Education Council (EC) Chair	Vakis Kontoes, Greece
EC Vice-Chair	Ozan Sozer, USA
Past President	Susumu Takayanagi, Japan
Trustee	Lokesh Kumar, India
Trustee	Carlos Uebel, Brazil
Executive Director	Catherine Foss, USA

### Standing Committee Chairs

Executive	Renato Saltz, USA
Nominating	Susumu Takayanagi, Japan
Membership	Ivar van Heijningen, Belgium
By-Laws	Tom Davis, USA
Communications	Arturo Ramirez-Montanana, Mexico
Patient Safety	Foad Nahai, USA
Journal Operations	Dirk Richter, Germany
Finance & Investment	Kai Schlaudraff, Switzerland
Newsletter	J. Peter Rubin, USA

### Education Council

Vakis Kontoes, Greece – Chair  
Ozan Sozer, USA – Vice Chair

### Ad Hoc Committee Chairs

Humanitarian	Tunc Tiryaki, Turkey
Industry Relations	Hani Zeini, USA
Insurance	Carlos Parreira, Portugal
Global Survey	Arturo Ramirez-Montanana, Mexico
Residents & Fellows	Maria Wiedner, Germany
Global Accreditation	Ozan Sozer, USA & Ivar van Heijningen, Belgium

### Task Force Chairs

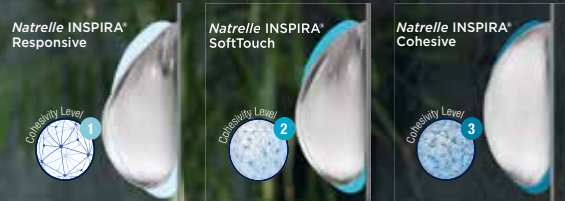Branding Task Force  
Julie Guest, USA

## DISCLAIMER:

ISAPS News is not responsible for facts as presented by the authors or advertisers. This newsletter presents current scientific information and opinions pertinent to medical professionals. It does not provide advice concerning specific diagnosis and treatment of individual cases and is not intended for use by the layperson. Readers are strongly advised to confirm that the information complies with the latest legislation and standards of practice. ISAPS, the editors, the authors, and the publisher will not be responsible for any errors or liable for actions taken as a result of information or opinions expressed in this newsletter. Copyright © 2018 by the International Society of Aesthetic Plastic Surgery, Inc. All rights reserved. Contents may not be reproduced in whole or in part without written permission of ISAPS.

# Natrelle®

Only Natrelle INSPIRA®  
DOES GUMMY LIKE THIS



Three cohesivities. Countless possibilities.<sup>1,\*</sup>

\*600 breast implant options.

“ Goodbye,  
padded bras.  
HELLO, NEW LOOK!”

**Emily**

Actual Natrelle INSPIRA® Cohesive  
primary augmentation patient.

Individual results may vary.

**Natrelle® Breast Implants Important Information**

**INDICATIONS**

Natrelle® Breast Implants are indicated for women for the following:

**Breast augmentation for women at least 22 years old for silicone-filled implants.**

Breast augmentation includes primary breast augmentation to increase breast size, as well as revision surgery to correct or improve the result of a primary breast augmentation surgery.

**IMPORTANT SAFETY INFORMATION**

**CONTRAINDICATIONS**

Breast implant surgery should not be performed in:

- Women with active infection anywhere in their body.
- Women with existing cancer or precancer of their breast who have not received adequate treatment for those conditions.
- Women who are currently pregnant or nursing.

**WARNINGS**

- Breast implants are not lifetime devices or necessarily a one-time surgery.
- Avoid damage during surgery: Care should be taken to avoid the use of excessive force and to minimize handling of the implant. Use care when using surgical instruments in proximity with the breast implant. For more information, please see the full Directions for Use.

**PRECAUTIONS**

Safety and effectiveness have not been established in patients with the following:

- Autoimmune diseases (eg, lupus and scleroderma).
- A compromised immune system (eg, currently receiving immunosuppressive therapy).
- Planned chemotherapy following breast implant placement.

- Planned radiation therapy to the breast following breast implant placement.
- Conditions or medications that interfere with wound healing and blood clotting.
- Reduced blood supply to breast tissue.
- Clinical diagnosis of depression or other mental health disorders, including body dysmorphic disorder and eating disorders. Please discuss any history of mental health disorders prior to surgery. Patients with a diagnosis of depression, or other mental health disorders, should wait until resolution or stabilization of these conditions prior to undergoing breast implantation surgery.

**ADVERSE EVENTS**

Key adverse events are reoperation, implant removal with or without replacement, implant rupture with silicone-filled implants, and capsular contracture Baker Grade III/IV.

Other potential adverse events that may occur with breast implant surgery include: asymmetry, breast pain, breast/skin sensation changes, capsular calcification, delayed wound healing, hematoma, hypertrophic scarring/scarring, implant extrusion, implant malposition, implant palpability/visibility, infection, nipple complications, redness, seroma, swelling, tissue/skin necrosis, wrinkling/rippling.

For more information see the full Directions for Use at [www.allergan.com/labeling/usa.htm](http://www.allergan.com/labeling/usa.htm). To report a problem with Natrelle® Breast Implants, please call Allergan at 1-800-433-8871.

Natrelle® Breast Implants are available by prescription only.

Reference: 1. Data on file, Allergan, January 2017; Allergan Plastic Surgery Order Form.

Contact your Allergan sales representative or visit [NatrelleSurgeon.com](http://NatrelleSurgeon.com) to learn more.



© 2018 Allergan. All rights reserved. All trademarks are the property of their respective owners. Natrelle.com NAT113067 02/18 173355





# Did you know?

At POLYTECH, we currently offer the widest portfolio of breast implants.

In our *SublimeLine*<sup>®</sup> series, we provide a complete modular matrix of breast implants that is

- logical
- easy to understand
- simple to handle

For natural results, rely on our diversity!



[facebook.com/polytechhealth.en](https://facebook.com/polytechhealth.en)



[@polytechhealth](https://twitter.com/polytechhealth)



[youtube.com/user/polytechhealth](https://youtube.com/user/polytechhealth)



**POLYTECH**  
health & aesthetics

**POLYTECH Health & Aesthetics**

Altheimer Str. 32 | 64807 Dieburg | Germany

☎ 0049.6071.98630 | 📠 0049.6071.986330

✉ [info@polytechhealth.com](mailto:info@polytechhealth.com) | [www.polytechhealth.com](http://www.polytechhealth.com)